

Pictorial Quiz

Sana Iqbal¹, Mehwash Kashif²

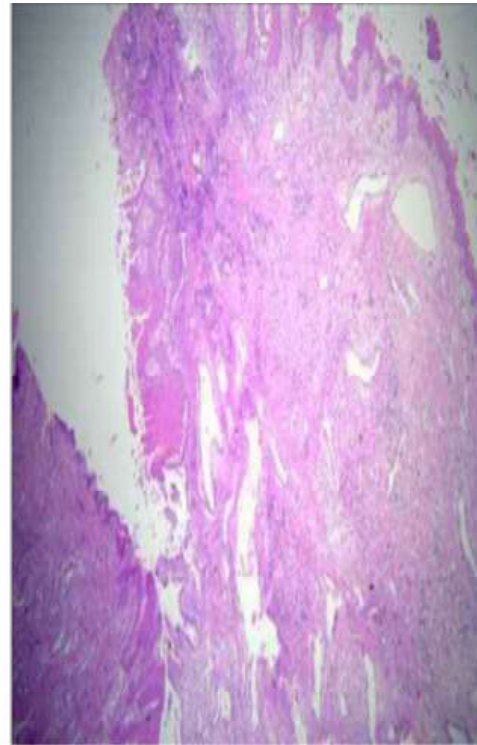
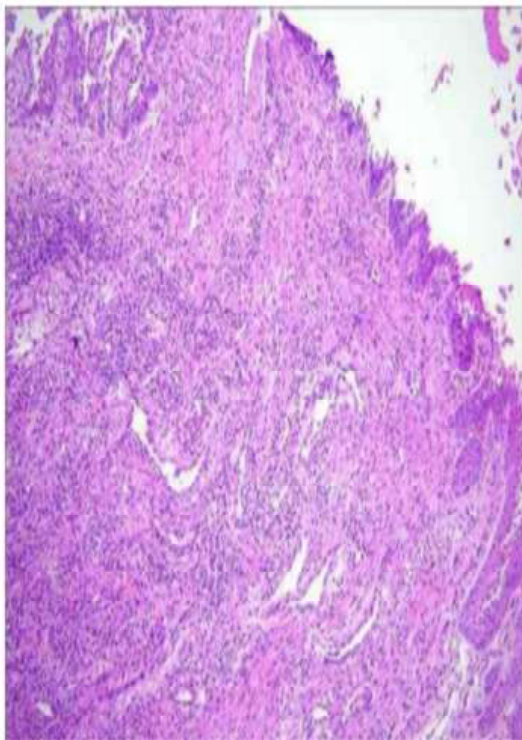
Case scenario

A 26-years - old female patient reported with the complaint of painless, slowly and persistently growing swelling on the left side of mandible for one year. Through oral examination revealed hard swelling on left side of mandible with no signs of inflammation and discharge. Lymph nodes were not palpable. Upon intraoral examination, a bony hard swelling was found, it was firm in consistency and purplish red in color. The size of the swelling was 1x12cm and was extending from second premolar to the first molar. No evidence of occlusion de-

range or paraesthesia. Orthopantomogram (OPG) showed a well circumscribed, unilocular radiolucency lesion on left side of mandible resorption first molar and displacement of second molar.

Histological examination of the section revealed stratified squamous lining with underlying tissue showing vascular channels and inflammatory cell infiltrate consisting of plasma cells and lymphocytes. There is no evidence of granuloma and malignancy.

What is your diagnosis?



¹⁻²Department of Oral Maxillofacial Surgery,
Karachi Medical and Dental College

Correspondence: Dr. Sana Iqbal
Department of Oral Maxillofacial Surgery, Abbasi
Shaheed Hospital & Karachi Medical & Dental College
Email: s_taurian@hotmail.com
Date of Submission: 28^h December 2020
Date of Acceptance: 31st May 2021

Answer on Page 295