

## Congenital Malaria in a Neonate: A Rare Condition

Fariha Raza<sup>1</sup>, Yusra Shariq<sup>2</sup>, Zoya Iqbal<sup>3</sup>, Salva Aghai<sup>4</sup>, Sina Aziz<sup>5</sup>

### Abstract

Malaria during first few months of life may be due to trans-placental transfer through a mother with parasitaemia. Congenital malaria has an occurrence rate of 0.3% in immune mothers and 7.4% in non-immune mothers. We report a case of 29 days old neonate, who presented with fever for 10 days, gross hepatosplenomegaly and anaemia (haemoglobin 6.0 gm/dl). Liver was palpable 3 cm below right subcostal margin with the span of 5.5 cm, non-tender, soft in consistency with regular margins and the spleen was palpable 3 cm below left subcostal margin. There were no signs of jaundice, dehydration and ascites and all other systems were normal. Peripheral blood films showed all stages of *Plasmodium vivax*. The baby was treated with initial boluses followed by intravenous (IV) fluids, and chloroquine was started at the standard cumulative dose of 10mg/kg, given in divided doses over 3 days. Four days after the treatment had been started; the baby's condition improved and was discharged. This report underlines that; diligent observation of blood film can accidentally reveal parasites, even when the diagnosis had not been previously suspected. Congenital malaria is a relatively rare condition that should be included in the differential diagnosis of neonatal infections, sepsis, and unexplained fever or in infants presenting with haemolytic anaemia, severe thrombocytopenia and hepatosplenomegaly in malaria endemic zones, even if the mother has no proven malarial episodes during the gestational period. It is therefore recommended that babies born to mothers with malaria should be screened for congenital malaria. The diagnosis should be considered in babies of mothers who have travelled to places where malaria is endemic, as maternal infection may be unrecognized, and the child may be asymptomatic at birth.

**Keywords:** Malaria, maternal-fetal exchange, transmission, *Plasmodium vivax*, newborn.

(ASH & KMDC 22(1):71;2017).

### Introduction

Congenital malaria is defined as malarial parasites demonstrated in the peripheral smear of the newborn from twenty-four hours to seven days of life<sup>1</sup>. Clinically apparent congenital malaria is rare in areas where malaria is endemic and levels of

maternal antibody are high. Congenital malaria has an occurrence rate of 0.3% in immune mothers and 7.4% in non-immune mothers<sup>2</sup>. The placenta acts as a barrier, hence, the presence of maternal antibodies and the protective effect of foetal haemoglobin (Hb F), congenital malaria has long been considered as a rare event. According to an estimate, there were about 219 million cases of malaria in 2010 and an estimated 660,000 deaths, mostly of children in Africa<sup>3</sup>. Malaria is still a major contributor to the high rate of the global infectious disease-related mortality and morbidity, particularly in Africa, South-East Asia, Eastern Mediterranean Regions and parts of South America (WHO 2008). In

<sup>1,2,4</sup> Final Year MBBS Students,

Karachi Medical and Dental College

<sup>3,5</sup> Department of Paediatrics, Abbasi Shaheed Hospital and Karachi Medical and Dental College

**Correspondence:** Dr. Fariha Raza

Final Year MBBS Students,

Karachi Medical and Dental College

Email: drfariha22@gmail.com

Date of Submission: 19<sup>th</sup> January 2017

Date of Acceptance: 28<sup>th</sup> February 2017

Eastern Mediterranean region, Pakistan is among the top 7 countries with high malarial transmission. As per an estimate, around 1.6 million cases including 300,000 confirmed cases at public sector healthcare facilities are reported in Pakistan every year. Although, globally since 2000, malaria mortality has fallen by more than 42%, but still 207 million malaria cases were reported in 2012, while 627,000 died of malaria in 2012 which included mostly infant, children and pregnant women<sup>4</sup>. Congenital malaria occurs in less than 5% of the affected pregnancies. Prevalence rates between 0.3% and 46.7% have been obtained from both endemic and non-endemic areas<sup>5</sup>. Malaria transmission in Pakistan is marked in post-monsoon season and mostly occurs after July-August. Congenital malaria is a cause of infant death and low birth weight according to World Health Organisation (WHO)<sup>6</sup>. Pregnant women and children under 5 years of age are the highest vulnerable group to malaria<sup>6</sup>. *Plasmodium vivax* is responsible for 13.8 million malaria cases globally in 2015 and to have accounted for about half the total number of malaria cases outside Africa. Severe cases and deaths due to *P. vivax* malaria have been reported from all endemic regions. Because of the difficulty in controlling *P. vivax*, its incidence has decreased more slowly than that of *P. falciparum* in locations where the two species coexist. *P. vivax* may then persist as the principal cause of malaria<sup>6</sup>. The rationale of this report is to highlight the information on the prevalence of congenital malaria, the clinical significance, diagnosis and treatment considerations, and its prevention.

### Case report

A 29 days old male baby of 4 kg weight, presented with fever for 10 days, reluctant to feed and showed marked pallor. The baby was on exclusive breast feeding since birth. On physical examination, the head circumference was 35.5 cm, length was 52 cm and the neonate was febrile, anaemic, hepatosplenomegaly was present; liver was palpable 3 cm below right subcostal margin with the span of 5.5 cm, non-tender, soft in consistency with

regular margins and the spleen was palpable 3 cm below left sub-costal margin. There were no signs of jaundice, dehydration and ascites and all other systems were normal. The heart rate was found to be 140 beats/min, blood pressure was 70/40 mmHg, respiratory rate was 40 breaths/min and temperature was 102°F. The neonate was therefore investigated for anaemia and hepatosplenomegaly. Major investigations were included complete blood count, peripheral smear, liver function tests, blood culture, dengue serology, C-reactive protein, Immunochromatographic test (ICT) malaria of mother and ultrasound abdomen.

Complete blood count revealed severe anaemia with haemoglobin 6.0 gm/dl, Mean corpuscular volume (MCV) 85 fl, Mean corpuscular haemoglobin (MCH) 27 pg, Total leucocyte count (TLC) 8100 cells/cu mm and platelets 42000 cells/cu mm. C-reactive protein was negative. The reticulocyte count was 0.3% and peripheral blood film showed anisocytosis and poikilocytes. Liver function tests (LFT) revealed total bilirubin of 1.8 mg/dl (direct 0.6 mg/dl and indirect 1.2 mg/dl), alkaline phosphatase 695 U/L and gamma-glutamyl transferase 135 U/L. Dengue serology was found to be negative and there was no growth on blood culture report. In a newborn with fever, anaemia and thrombocytopenia, we considered neonatal sepsis due to bacterial or viral infection as the most likely diagnosis. However, the diagnosis of congenital malaria was made by the identification of schizonts of *P. vivax* in the peripheral smear as this method has been recognised as the gold standard laboratory confirmation of congenital malaria. The baby was treated with initial boluses followed by appropriate intravenous fluids with glucose, and chloroquine was started at the standard cumulative dose of 10mg/kg, given in divided doses over 3 days. Panadol drops 10 mg/kg/dose were also given. He also received packed cell transfusion 10 cc/kg twice. Four days after treatment, the baby showed remarkable recovery, his fever had subsided and splenomegaly disappeared. The baby started to take breast milk normally. His TLC increased up to 13,400 cells/cu mm, haemoglobin 13.7 gm/dl and platelet count was 142,000

cells/cu mm. Repeated peripheral smear examination showed no malarial parasite. The infant was discharged on nutritional supplements and iron drops and was doing well on regular follow-up.

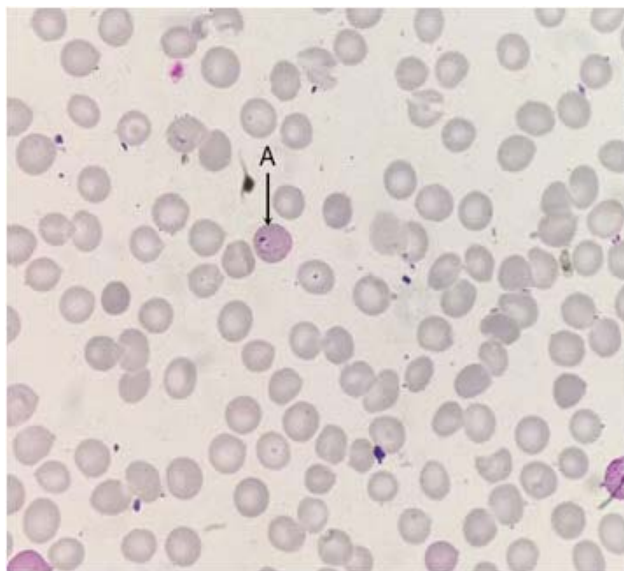


Fig 1. Peripheral smear of the neonate showing growing (A)-trophozoites (arrow).

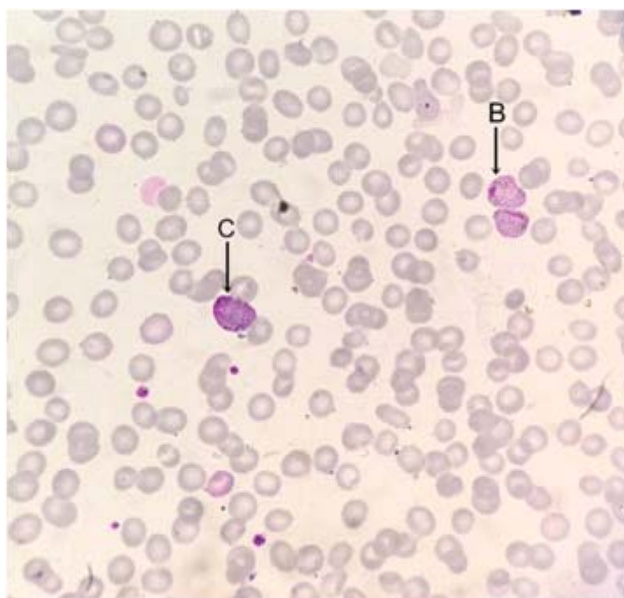


Fig 2. Peripheral smear of the neonate showing (B)-schizonts and (C)-gametocyte (arrow).

In view of the revised diagnosis, the history of the mother was re-evaluated. She had a history of febrile illness during the third trimester of pregnancy, however at that moment she did not have any fever. Her peripheral blood film was also positive for *P. vivax*. She was given a full course of anti-malarial treatment with chloroquine.

### Discussion

A study conducted in Karachi showed that the prevalence of congenital malaria was 4.45% and 14% in acquired malaria cases and *P. falciparum* and *P. vivax* are the most prevalent species in Karachi<sup>7</sup>. Malaria in pregnancy and newborns, causes significant burden of disease, and is estimated to cause more than 300,000 foetal and infant deaths and 2,500 deaths of pregnant women worldwide annually<sup>8</sup>. In endemic countries, congenital malaria is mainly caused by *P. falciparum*. Clinical features of neonatal malaria include anaemia (77%), fever (74%), liver and spleen enlargement (68%), poor feeding, lethargy/irritability and jaundice. Severe thrombocytopenia without bleeding is also a frequently reported feature of congenital malaria<sup>9</sup>. Prompt parasitological confirmation by microscopy or alternatively by rapid diagnostic tests (RDTs) is recommended in all patients with suspected malaria before treatment is started. Diagnosis is simple with microscopic examination of blood films, though a clinical suspicion of the disease is required to start an appropriate diagnostic procedure. This report underlines that the diagnosis can be achieved by diligent observation of parasites in a blood film, even when the diagnosis had not been previously suspected. The treatment of neonatal vivax malaria comprises of a blood schizonticide, such as chloroquine, in a dose of 10 mg/kg body weight of base followed by 5 mg/kg of base at 6, 24 and 48 h. Primaquine is not given in congenital malaria as there is no exoerythrocytic stage of the parasite<sup>10</sup>. The World Health Organisation (WHO) 20th Malaria Committee designated IPT (Intermittent preventive therapy) as the preferred approach to reduce the adverse consequences of malaria during pregnancy. Prompt treatment should be instituted to avoid as-

sociated morbidity and mortality. Blood film microscopy remains the gold standard for the diagnosis of congenital malaria and all the neonates with unexplained fever should be evaluated and treated with effective anti-malarial drugs. Health care professionals should be aware that congenital *P vivax* malaria does not need to be treated with primaquine. Early diagnosis could prevent unnecessary antibiotics usage and neonatal mortality. It is therefore recommended that babies born to mothers with malaria should be screened for this disease.

### Conclusion

To conclude, congenital malaria is a relatively rare condition that should be included in the differential diagnosis of neonatal infections, sepsis, and unexplained fever or in infants presenting with haemolytic anaemia, severe thrombocytopenia and hepatosplenomegaly in malaria endemic zones. An association was found between congenital malaria and the diagnosis of malaria in the mother during the last trimester of pregnancy.

### Conflict of Interest

Authors have no conflict of interests and no grant or funding from any organization

### References

1. Arvin AM, Maldonado YA. Protozoan and Helminth Infections. In: JS Remington, JO Klein, editors. Infectious Diseases of the Foetus and Newborn Infant. 4th ed. Philadelphia: WB Saunders; 1995. p. 765-8.
2. Krause PJ. Malaria (Plasmodium). In: Behrman RE, Kliegman RM, Jenson HB, editors. Nelson Textbook of Pediatrics. 17th ed. Philadelphia: WB Saunders; 2004. p. 139-43.
3. Malaria fact sheet of World Health Organization (WHO) [Internet]. Geneva: World Health Organization; 2013. Available from: <http://www.malarianimby.org/malaria-fact-sheet-of-world-health-organization-who/index.php>. Accessed on February 15, 2017.
4. Malaria is second most devastating disease in Pakistan [Internet]. Pakistan Times; 2015. Available from: <http://news.pakistantimes.com/2015/04/25/malaria-is-second-most-devastating-disease-in-pakistan-365674.html>. Accessed on February 15, 2017.
5. Fischer PR. Malaria and newborns. *J Trop Pediatr* 2003;49:132-4.
6. World Malaria Report 2015 [Internet]. Geneva: World Health Organization; 2015. Available from: [http://apps.who.int/iris/bitstream/10665/200018/1/9789241565158\\_eng.pdf?ua=1](http://apps.who.int/iris/bitstream/10665/200018/1/9789241565158_eng.pdf?ua=1). Accessed on February 15, 2017.
7. Zafar T. Hematological studies during congenital and acquired malaria of human in Karachi west. PhD thesis. University of Karachi, Karachi, 1997.
8. Menendez C, D'Alessandro U, terKuile FO. Reducing the burden of malaria in pregnancy by preventive strategies. *Lancet Infect Dis* 2007;7:126-35.
9. Lesko CR, Arguin PM, Newman RD. Congenital malaria in the United States: a review of cases from 1966 to 2005. *Arch Pediatr Adolesc Med* 2007;161:1062-7.
10. Del Punta V, Gulletta M, Matteelli A, Spinoni V, Regazzoli A, Castelli F. Congenital Plasmodium vivax malaria mimicking neonatal sepsis: a case report. *Malar J* 2010;9:63.