

# Open Approach Rhinoplasty for Correction of Nasal Deformities in Tertiary Care Hospital

Fareya Usmani<sup>1</sup>, Syed Mosaddaque Iqbal<sup>2</sup>, Mukhtar Ibrahimi<sup>3</sup>,  
Syed Iqbal Hussain<sup>4</sup>, Sohail Tirmizi<sup>5</sup>, Imran Munir<sup>6</sup>, Aftab Imtiaz<sup>7</sup>

## Abstract

**Objective:** To study reasons for open rhinoplasty procedure and evaluate complications and outcomes.  
**Methods:** This prospective Cohort study was conducted from Sept. 2012 - Oct. 2019 at Department of ENT/Head & Neck Surgery, Sir Syed Medical College and Jamal Noor Hospital Karachi after ethical approval. Total 49 patients included by consecutive sampling. Adult patients (>18 years, both genders) presenting with functional and aesthetic nasal issues were included that underwent open approach rhinoplasty. Patients who underwent rhinoplasty earlier, with residual deformity, with cleft lip or palate and who lost follow up before a year were excluded. Demographic details, indications for surgery and clinical findings documented on specially designed proforma. Photograph record obtained preoperatively, third post-operative day, three monthly till one year.

**Results:** Amongst 49 cases (15 males & 34 females), between 22-31 years age. Most common reasons were grossly deviated nose 58%, saddle nose 23%, dorsal hump 17% and crooked nose 7%. Most cases had nasal tip deformities (i.e. under projected, rotation or asymmetry). Complications observed were septal hematoma (2 cases), poly beak deformity, nasal valve stenosis and periorbital edema on each patient. Mean time for nasal packing was 12 hours, and hospital stay was 24 hours. One patient required revision surgery for poly beak deformity and one for nasal valve stenosis. External scar (columellar) were invisible after few months in all cases.

**Conclusion:** Open rhinoplasty is the preferred, safe and effective procedure with promising results. This approach allows accurate anatomical detail of nasal framework (osteo-cartilaginous vault). Further options are available to deal with original tissues and graft materials as well as suture stabilization of grafts with ease and additional benefits. Satisfactory results with minimal side effects are reasons for preferable use of this procedure.

**Key words:** Nasal deformity, open rhinoplasty, nasal septum & nasal conchal.

**IRB:** Approved by ethical review committee of Sir Syed Hospital. Dated: 14<sup>th</sup> January 2020.

**Citation:** Usmani F, Iqbal SM, Ibrahimi M, Hussain SI, Tirmizi S, Munir I, et al. Open Approach Rhinoplasty for Correction of Nasal Deformities in Tertiary care Hospital.[Online] Annals ASH KMDC 2020;25:

(ASH & KMDC 25(2):82;2020)

## Introduction

Rhinoplasty is amongst the most complex and challenging surgical procedures. The nose with its

<sup>1-2</sup>Department of Surgery

Sir Syed Medical College

<sup>3</sup>Department of ENT

Indus Medical College Tando Mohammad Khan.

<sup>4</sup>Consultant Head and Neck Surgery,

Sindh Institute of Urology and Transplantation

<sup>5</sup>Department of ENT

Hamdard College of Medicine and Dentistry Karachi

<sup>6</sup>Consultant General Surgeon

Bahria International Hospital Karachi.

<sup>7</sup>Professor Head of the Department of Anesthesia

Abbasi Shaheed Hospital

**Correspondence:** Dr. Fareya Usmani  
Department of Surgery, Sir Syed Medical College

Email: fareyausmani@gmail.com

Date of Submission: 29<sup>th</sup> January 2020

Date of Acceptance: 8<sup>th</sup> September 2020

complex function and three-dimensional anatomy interferes with respiratory, emotional behavioral and immunological factors<sup>14</sup>.

Rhinoplasty was said to be a procedure that is not too difficult to carry out but extremely challenging for consistent outstanding results. Rhinoplasty changed considerably in the last decade from a standardized reduction procedure to a highly differentiated problem-oriented procedure where reductions, relocations and augmentations of the tissues are frequently combined. In addition, different techniques are popular among various schools of thought.

John Orlando Roe entered history as the father of aesthetic rhinoplasty after having reported a "simple operation" in 1887 describing the correction of a "pug nose" through an endonasal approach. Four years later Roe performed endonasal hump reductions.

In 1892 Weir described the technique of "nasal infarction" augmented saddle nose with implants made of duck-sternum and described the rotation of the drooping tip by a wedge excision from the caudal septum. The latter technique is still named after him today. The first transplantation of costal cartilage was published by Mangoldt in 1900. In the US, the number of facial plastic surgical procedures increased by 34% between 2000 and 2004, the most popular aesthetic procedures were blepharoplasty followed by rhinoplasty .

Preoperative considerations like systematic nasal analysis is critical when evaluating a patient for rhinoplasty. The nasal frontal angle height and depth, the bony pyramid, upper and lower lateral cartilages, nasal tip projection, rotation, symmetry, and position of tip defining points, alar width, collapse, or retraction, columellar show and angles must all be considered. In addition, a naso-facial analysis must also be performed. The lip to chin relationship is important and can be assessed on a lateral photograph.

Once the decision to perform a rhinoplasty has been made, the surgeon must determine the best operative approach, open versus closed. Closed or endonasal approach emphasize on its advantages, namely, absence of external incisions and less dissection, therefore minimizing soft tissue trauma, subsequent scarring with rapid recovery. It is less dependent on postoperative steroids to reduce postoperative swelling. However, exposure to the surgical field is very limited and tip supporting mechanism tends to be compromised with time, while this approach is ideal for patients requiring minimal tip work.

On the contrary, the open or external approach offers a much superior exposure of the nasal tip for

inspection of the nasal osteo-cartilaginous framework without anatomic distortion, therefore allowing proper remodeling of the nasal framework. The surgeon can be assured of accuracy while performing detail suturing and resection manipulation. It also offers unparallel accuracy for structural diagnosis and placement or manipulation of graft, if needed, under direct vision .

Open rhinoplasty became more popular during the last ten years because of many obvious indications like, asymmetry of upper lateral cartilage or alar cartilages, crooked nose, saddle nose, nasal tip deformities, septal deformities and in revision surgeries .

In addition, with open approach there are many options with manipulation of nasal tissues and grafts as well as suture fixation of grafts. In the treatment of crooked nose, open rhinoplasty approach is very helpful by improving intraoperative appraisal and facilitating suturing of the grafts. Thorough clinical assessment and logical, sequenced operative planning impacts on the outcome of rhinoplasty which is more easily achievable with the open approach rhinoplasty.

There are limited regional studies available regarding open approach rhinoplasty. The results from current study will be helpful to highlight the reasons, complications and results of this procedure in our patients. This also addresses the importance of post-operative follow up after this procedure and the possible complications. The data from this study will be helpful to compare with regional and international studies.

## **Patients and Methods**

This prospective cohort study was conducted over seven years (1st September 2012 - 31st Oct 2019) at Department of ENT and Head & Neck Surgery, Sir Syed Medical College and Jamal Noor Hospital Karachi after ethical approval. We included 49 patients by consecutive sampling. Sample size was calculated using 95% confidence interval, relative precision 13% and 22% prevalence of nasal de-

formities with minimal sample size of 39. Adult patients (>18 years, both genders) presenting with functional and aesthetic nasal issues were included that underwent open approach rhinoplasty. Patients who underwent rhinoplasty earlier, with residual deformity, with cleft lip or palate and who lost follow up before a year were excluded.

A complete history, thorough clinical examination and full preoperative evaluation including photos, informed consent with counselling and evaluation by psychologist for documentation were performed in all patients. Open approach rhinoplasty (septo-rhinoplasty) under general anesthesia was the approach for all of our 49 cases.

In open rhinoplasty, after the local infiltration of xylocaine with adrenaline 1:200000 solution in the nose followed by a trans columellar incision anterior to the medial crus footplate was given. The marginal incision bilaterally in vertical columella 2mm inside the vestibule was given while taking care not to damage the medial crura. With a sharp scissor, the columellar incision was joined with the marginal incisions, and the marginal incision was extended up to halfway along the vestibulum for adequate exposure of the nasal skeleton without disturbing the soft triangle of converse to avoid alar retraction. To prevent the intraoperative bleeding, the dissection was done in the sub-perichondrial plane and to free the cartilaginous vault, the dissection was continued in the midline between the domes. Soft tissue dissection over the bony pyramid was carried in the subperiosteal plane 2-3 mm above and parallel to the caudal end of nasal bones. The hump osteotome (10-14 mm width) was used for the removal of the osteo-cartilaginous hump.

The columella incision was closed with non-absorbable (5/0) sutures, starting from the midline keeping the edges everted for better healing and less visible scar. To prevent the postoperative bleeding, synechia and hematoma formation intranasal packing was applied. External nasal taping and dressing was also done to reduce the dead space and hematoma formation. Nasal splint was

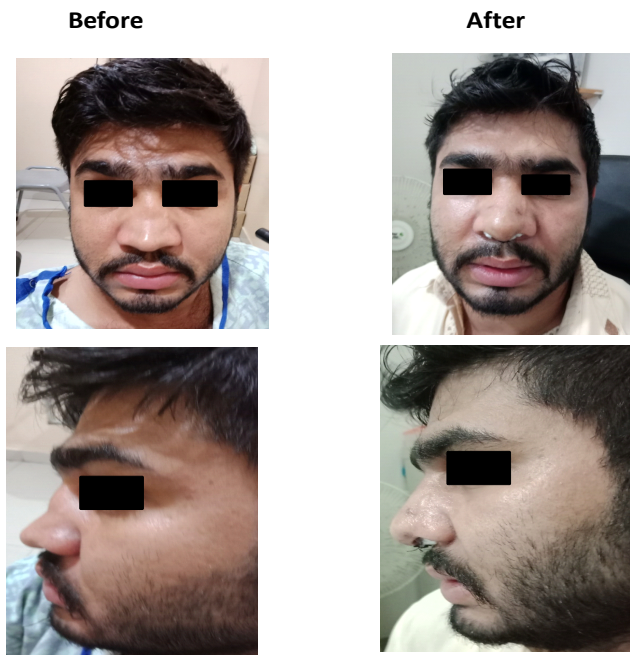also applied over the bridge of the nose to prevent the distortion during facial musculature mobility.

Majority of our cases with nasal deformity and nasal obstruction (DNS) of S shape, posterior deviation and anterior septal dislocation or crooked nose underwent septo-rhinoplasty. In cases of hump nose, humpectomy, osteotomies followed by sprader and columellar graft was placed. In all the cases autogenous grafts were used such as: septal cartilage, conchal cartilage while in one patient a piece of iliac crest was used. For the nasal tip deformities, the lower lateral cartilages were trimmed, columella strut placed and sutured with the medial crus. Also, interdermal & transdermal sutures were given when needed.

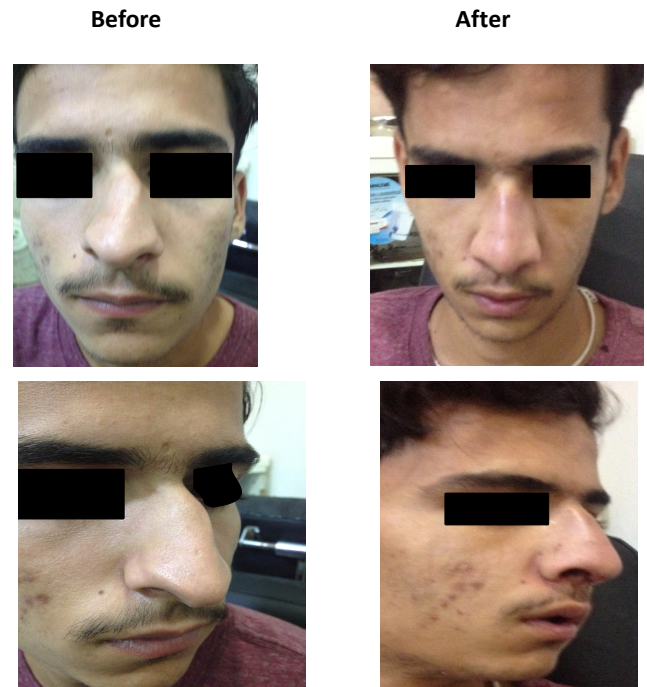For low nasal dorsum or saddle nose, augmentation can be achieved by different graft materials, alloplastic materials including silicone, polytetrafluoroethylene (PTFE) and Medpor has good results but more chances of extrusions and infections while autografts like septal and conchal cartilages or rib are well tolerated by the body with lower risk of infections and long term survival. In our patients we harvested septal and conchal cartilages and diced cartilage were draped with temporalis fascia for dorsal augmentations.

For nasal tip deformities like under-projected and the one lacking in definition, we used septal as well as conchal cartilage grafts as columella struts along with lateral crural struts grafts to strengthen the cartilaginous framework. A convex dorsal hump was reduced in many of our cases but some of them also required tip augmentation. Major complications in rhinoplasty like infections, displacement of grafts, skin discolorations and calcifications are more with allografts (silicone implants). However, complications less likely occurred with the use of autografts (septal and conchal cartilages).

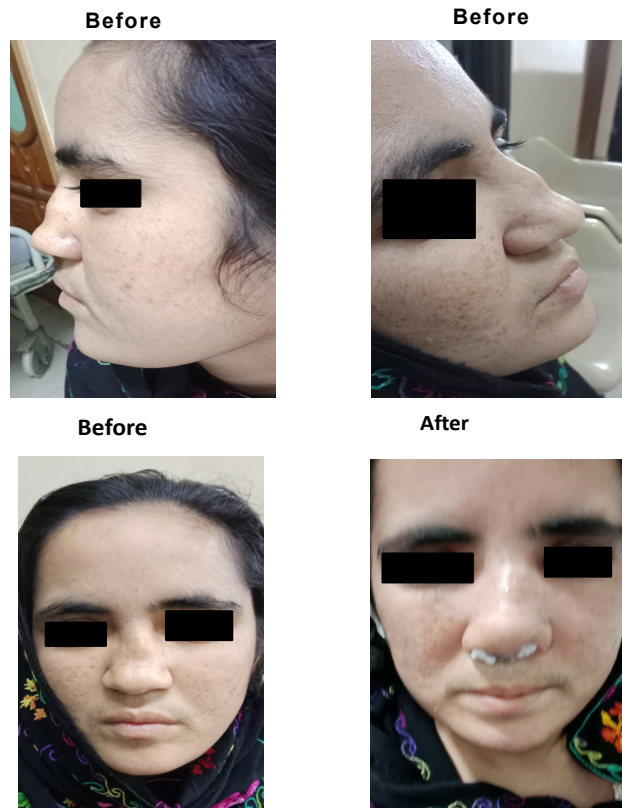For our record we kept the photographs of all the cases as a preoperative photo, within few days after surgery then after 3 months, and 6 months and lastly, at the end of first year (Fig.1). Data was documented on specially designed proforma and



**Fig 1.** Pictures of a male patient representing the preoperative versus one-year post-operative results after the Rhinoplasty procedure.



**Fig 2.** Pictures of another male patient representing the preoperative versus one-year post-operative results after the Septo-rhinoplasty procedure.



**Fig 3.** Pictures of a female patient representing the preoperative versus one-year post-operative results after the rhinoplasty procedure.

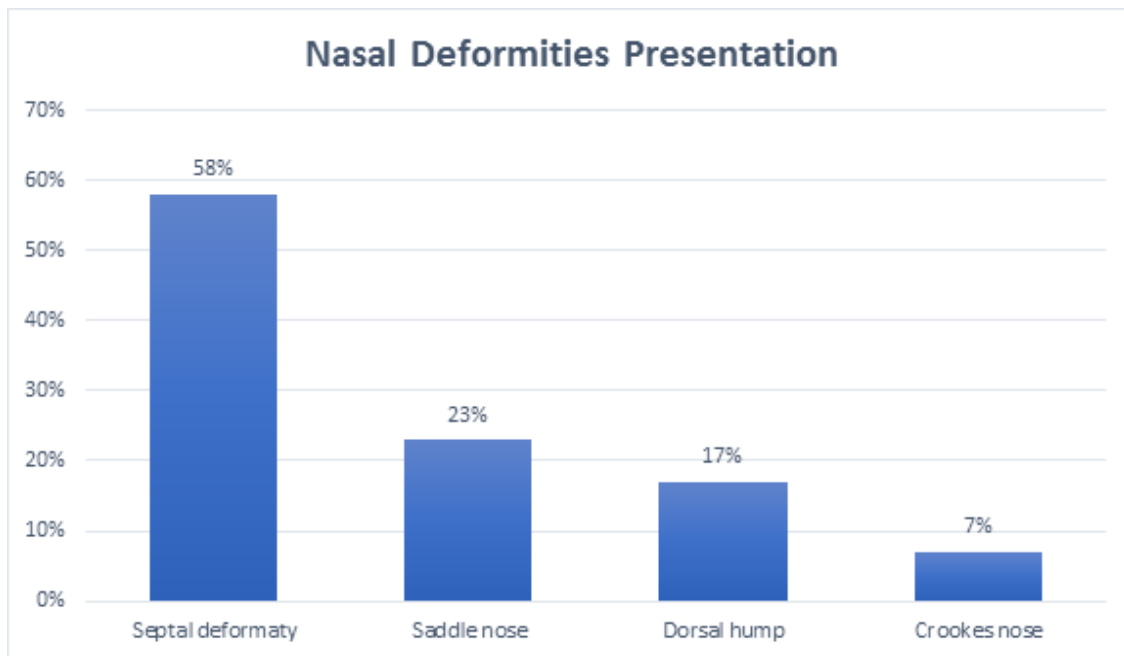


Fig 4. A bar graph demonstration of the nasal deformities observed (n=49).

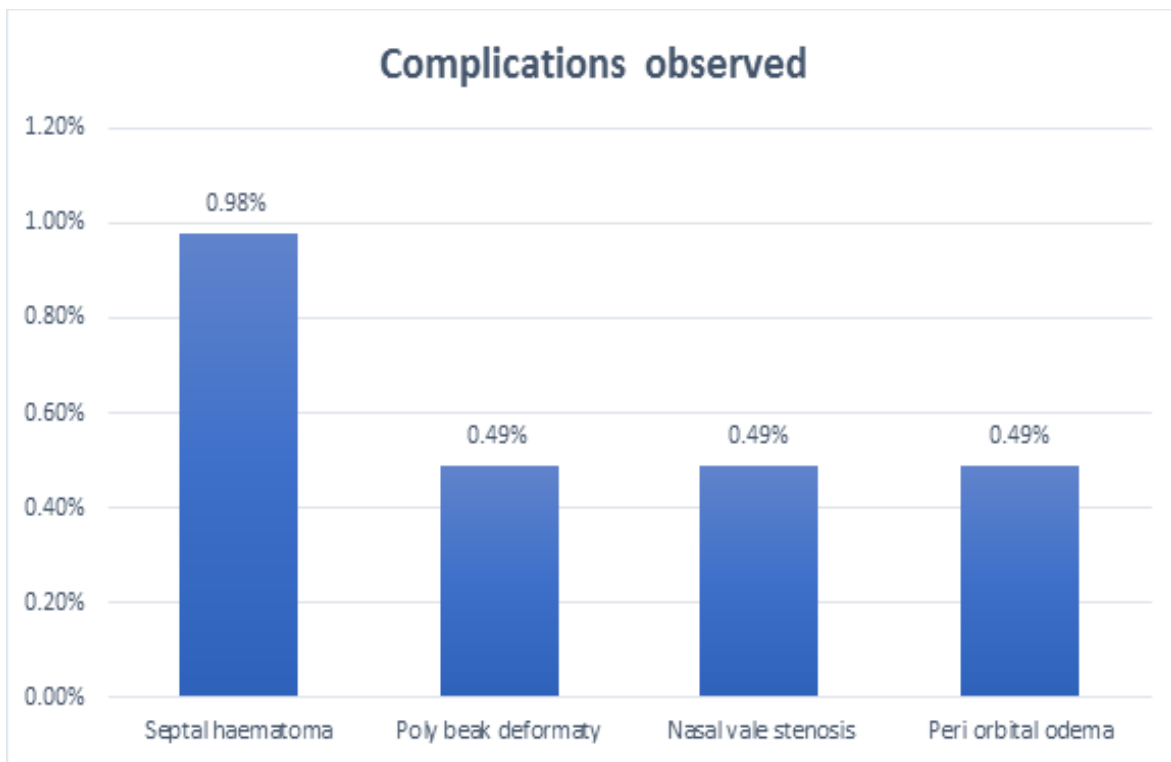


Fig 5. A bar graph demonstration of the post-operative complications of open approach rhinoplasty (n=49).

analyzed via SPSS version 21. For quantitative variables (i.e. age) mean and standard deviation was calculated and for qualitative variables (i.e. gender, nasal deformities, complications) frequencies and percentages were calculated. Data is presented in the form of bar graphs. Pictures of the patients are also attached to compare the results with consent of each case.

## Results

Total 49 patients with different nasal deformities were admitted in our department of Otorhinolaryngology. Out of 49 patients, 34 were females and 15 were males. They were all young adults between 22 to 31 years of age and majority were having history of trauma. Majority of these patients presented with septal deviation (58%), saddle nose (23%), dorsal hump (17%), crooked nose and tip deformities (7%) and nasal obstruction. (Fig. 4). Most of the patients had nasal tip deformities i.e. nasal tip was either under projected, rotated or asymmetrical.

In majority cases, the post-operative period was uneventful but two of our patients developed septal hematoma, one poly beak deformity, one nasal valve stenosis and only one developed periorbital edema; all of them were dealt accordingly (Fig. 5).

The mean time for nasal packing was 12 hours, and hospital stay was 24 hours. Osteotomy was done with micro osteotome which lead to negligible periorbital ecchymosis for less than 5 days. Only two cases had to undergo revision surgery: one for Poly beak deformity and the other due to post-operative nasal valve stenosis. The pictures of few reference cases pre-operative and one-year post-operatively are given hereby (Fig 1, 2 & 3).

## Discussion

Rhinoplasty is one of the most challenging operations and optimal outcomes do not result from choosing an open or closed approach. During the procedure, many factors affect the results, including

analysis of nasal anatomy, selection of surgical technique, degree of trauma to soft tissues, cartilages and amount of bleeding during the procedure. All of these factors have great impact on the results.

The closed approach has been demeaned quickly as the open approach provides better visualization for the purpose of examination, surgery and learning/teaching. Furthermore, the evolving procedures like tip suturing, advanced septal reconstruction, and mid-vault reconstruction which were basically impractical via closed approach have been now achieved via open approach. Finally, learning to operate via closed approach has been found to be difficult compared with learning the open approach. Open approach has shown more acceptance and better results among various ethnic groups as compared to closed approach. Still, there are surgeons who advocate the closed endonasal approach for rhinoplasty but both approaches have their pros and cons and should be followed accordingly.

The external or open approach is essentially a more aggressive form of delivery. It is advisable to use this procedure when the nasal tip is highly asymmetrical, markedly over projected, severely under projected, or anatomically distorted as in secondary revision cases. Open rhinoplasty fairly addresses the issues of nose size, shape, angle and hump.

The open rhinoplasty allows more accurate anatomic diagnosis with undistorted exposure for consistent and reliable modification of nasal frame work. This open exposure also helps in structural alterations and easier bimanual sculpturing under direct vision. This is why the external approach has gained enormous popularity in rhinoplastic surgery.

Modern methods and multiple suture techniques to correct nasal tip deformities like, use of cartilage grafts, columellar strut, interdomal, transdomal and intercrural suture techniques are much easier and better done via open approach which is highly indicated in saddle nose, crooked

nose, nasal tip asymmetry or deformity and revision rhinoplasty. The columellar strut graft or batten graft clarifies the nasal tip definition through an interdomal suture and maintains the position against pulling forces exerted by the depressor septi nasi muscle contraction and skin sutures.

Shafaei Y et al conducted a study in which they compared spreader graft and spreader flap techniques in terms of aesthetic outcomes and respiratory side effects during open rhinoplasty when reducing nasal hump and to maintain a wide nasal valve angle. The authors did not find superiority of one technique over the other except that the spreader graft increases the incidence of nasal hump while the spreader flap technique raises the incidence of obstructive sleep apnea, concluding that both the techniques may effectively be used considering the individual patient's clinical scenario.

Surgical procedures such as trans fixation incisions, cephalic trim, inter-cartilaginous incisions, and medial division of the LLCs disrupt the support and cause changes in the tip position. Therefore, reinforcement of the nasal tip is required in most cases in such procedures .

Literature shows that prevalence of nasal septal deviation varies between 20-31%. Crosara PF and colleagues carried out a systematic review in which they studied the complications of open/closed rhinoplasty and reoperations (revision surgeries). The authors found that out of 11035 rhinoplasties performed, 9655 (87.5%) were primary surgeries while 1380 (12.5%) were secondary/revision surgeries. The percentage of primary surgeries performed via open approach was 89% and via closed approach was 11%. The authors also concluded that the percentage of secondary surgeries performed via open approach was 20.2% and that through the closed approach was 43.0%. Secondary rhinoplasties were performed mainly due to untreated or unsatisfactory results that comprised of 22.5% nasal tip, 16.4% nasal valve, 8.9% nasal wings, 27.9% nasal dorsum, 20.1% nasal pyramid and 3.9% columella nasal issues. The authors therefore concluded that the choice of approach

(open or closed) in the primary surgery doesn't interfere or depict the rate of secondary or revised surgeries.

Open rhinoplasty in revision cases for aesthetic issues and tip asymmetries is a much easier approach to achieve the required goals. Open approach rhinoplasty is more traumatic in comparison with closed rhinoplasty, with more postoperative supra tip edema and a columellar scar which is invisible in most of the cases with time.

Between the debate of pros and cons of both the open and closed approaches for rhinoplasty, Inchingolo Fet al , described a third "semi-open" approach for rhinoplasty. This technique is performed by giving an incision to expose the mucosa of both the nostrils, and with this access the cartilages of the columella are separated from the alar cartilages, followed by the debridement of the cartilages at the domus. This technique has advantages over open approach including absence of post-surgical scarring. However, this technique has to undergo number of trials before being generalized.

## Conclusion

Open rhinoplasty ensures a full exposure of the nasal osteo-cartilagenous vault and provides easier access to apply all modern methods, sutures and grafts placement techniques to correct the nasal hump or saddle nose problems and tip deformities to achieve the goals.

## Conflict of Interests

Authors have no conflict of interests and received no grant/funding from any organization.

## References

1. Paulo Fernando Tormin Borges Crosara, Flavio Barbosa Nunes, et al. Rhinoplasty Complications and Reoperations. *Int Arch Otorhinolaryngology* 2017; 21:97-101. [DOI: 10.1055/s-0036-1586489]
2. Gunter JP, Rohrich RJ, Adams WP, editors. *Dallas rhinoplasty: nasal surgery by the masters*. Quality Medical Publishing: St. Louis; 2002.

3. Sheen JH. Rhinoplasty: personal evolution and milestones. *Plast Reconstr Surg* 2000; 105: 1820-52. [DOI: 10.1097/00006534-200004050-00033]
4. Stucker FJ. Rhinoplasty from the Goldman/Cottle schools to the present: a survey of 7447 personal cases. *Am J Rhinol* 2003;17:23-26.
5. Hauben DJ. Die Geschichte der Rhinoplastik. *Laryngo Rhinol Otol* 1983; 62: 53-54.
6. American Academy of Facial Plastic and Reconstructive Surgery [Internet]. Membership Survey: Trends in Facial Plastic Surgery. March, 2005. [Available from: <http://legacy.aafprs.org/wp-content/themes/aafprs/pdf/AAFPRSMEDIA2005.pdf>. Accessed on: 14 July 2020]
7. Byrd HS. Rhinoplasty. *Selected Readings in Plastic Surgery* 2001; 9:1-52.
8. Scattolin A, D'Ascanio L. Grafts in "closed rhinoplasty". *Acta Otorhinolaryngol Ital* 2013;33:169-76.
9. Petropoulos I, Karagiannidis K, Kontzoglou G. Our Experience in open rhinoplasty. *Hipokratia* 2007; 11:35-8.
10. Janis JE, Rohrich RJ. Rhinoplasty. In: Thorne CH, Beasley RW, Aston SJ, editors. *Grabb and Smith's Plastic Surgery*. 6th ed. Philadelphia, PA: Lippincott Williams & Wilkins; 2007.p. 517-32.
11. Rohrich RJ, Muzaffar AR. Primary Rhinoplasty. In: Mathes SJ, Hentz VR, editors. *Plastic Surgery*. vol2, 2nd ed. Philadelphia, PA: Saunders; 2006. p.427-71.
12. Tebbetts JB. Open and Closed Rhinoplasty: Analyzing Processes. *Aesthet Surg J* 2006;26: 456-9. [DOI: 10.1016/j.asj.2006.06.003]
13. Toriumi DM, Pero CD. Asian rhinoplasty. *Clin Plast Surg* 2010;37:335-52. [DOI: 10.1016/j.cps.2009.12.008]
14. Jang YJ. Asian rhinoplasty. In: Papel ID, Fordel JL, Holt GR, editors. *Facial Plastic and Reconstructive Surgery* 3rd ed. New York: Thieme Medical Publishers; 2009.p. 619-37.
15. Kim EK, Daniel RK. Operative techniques in Asian rhinoplasty. *Aesthet Surg J* 2012;32:1018-30. [DOI: 10.1177/1090820X12462716]
16. McCurdy JA, Lam SM. Cosmetic Surgery of the Asian face. In: McCurdy JA.; Lam SM editors. 2nd ed. New York: Thieme Medical Publishers; 2005.
17. Lee CS. Asian rhinoplasty treatment and management [Online]. *Medscape emedicine*; 2016 [Updated on: 2016 Oct 14; cited 2019 Sep 17]. [Available from: <http://emedicine.medscape.com/article/1293426-treatment>. Accessed on:14 July 2020].
18. Izu SC, Kosugi EM, Brandao KV, et al. Normal values for the Rhinoplasty Outcome Evaluation (ROE) questionnaire. *Braz J Otorhinolaryngol* 2012; 78: 76-9. [DOI: 10.1590/s1808-86942012000400015]
19. Gendeh BS. Clinical study of graft selection in Malaysian rhinoplasty patients. *ISRN Otolaryngology* 2013; 639643.. [DOI:10.1155/2013/639643]
20. Constantain MB. The two essential elements for planning tip surgery in primary and secondary rhinoplasty: observation based on review of 100 consecutive patients. *Plast Reconstr Surg* 2004; 114:1571-80. [DOI: 10.1097/01.prs.0000138755.00167.f5]
21. Daniel RK, Brenner KA. Saddle nose deformity: a new classification and treatment. *Facial Plast Surg Clin North Am* 2006; 14:301-12. [DOI:10.1016/j.fsc.2006.06.008]
22. Whitaker EG, Johnson Cm Jr. The evolution of open structure rhinoplasty. *Arch Facial Plast Surg* 2003; 5:291-300. [DOI:10.1001/archfaci.5.4.291]
23. Park SG, Jeong H, Ye CH. Multifactorial approaches for correction of the drooping tip of a long nose in East Asians. *Arch Plast Surg* 2014; 41:630-37. [DOI:10.5999/aps.2014.41.6.630]
24. Shafaei Y, Zare NJ. A Comparison of the Aesthetics Outcomes and Respiratory Side Effects of the Use of Spreader Flap and Spreader Graft Techniques in Open Rhinoplasty. *J Craniofac Surg* 2019;30:2546-48. [DOI:10.1097/SCS.00000000000005744]
25. Dhong ES, Kim YJ, Suh MK. L-shaped columellar strut in East Asian nasal tip plasty. *Arch Plast Surg* 2013;40:616-20. [DOI: 10.5999/aps.2013.40.5.616]
26. Madani SA, Hashemi S A, Modanluo M. The incidence of nasal septal deviation and its relation with chronic rhinosinusitis in patients undergoing functional endoscopic sinus surgery. *J Pak Med Assoc* 2015; 65: 612-14.
27. Crosara PF, Nunes FB, Rodrigues DS, Figueiredo ARP, Becker HMG, Becker CG et al. Rhinoplasty Complications and Reoperations: Systematic Review. *Int Arch Otorhinolaryngol* 2017;21:97-101. [DOI: 0.1055/s-0036-1586489]
28. Constantain MB. Nasal tip sutures part II. *Plast Reconstr Surg* 2002; 4: 444-51. (please ask to review this reference as it cannot be found)
29. Inchingolo F, Tatullo M, Marrelli M, Inchingolo AD, Corelli R, Inchingolo AM, et al. Semi-open rhinoplasty: a new maxillofacial technique. *Head Face Med* 2012;8:13. [DOI: 10.1186/1746-160X-8-13]