

Pictorial Quiz

Sana Iqbal¹, Mehwash Kashif²

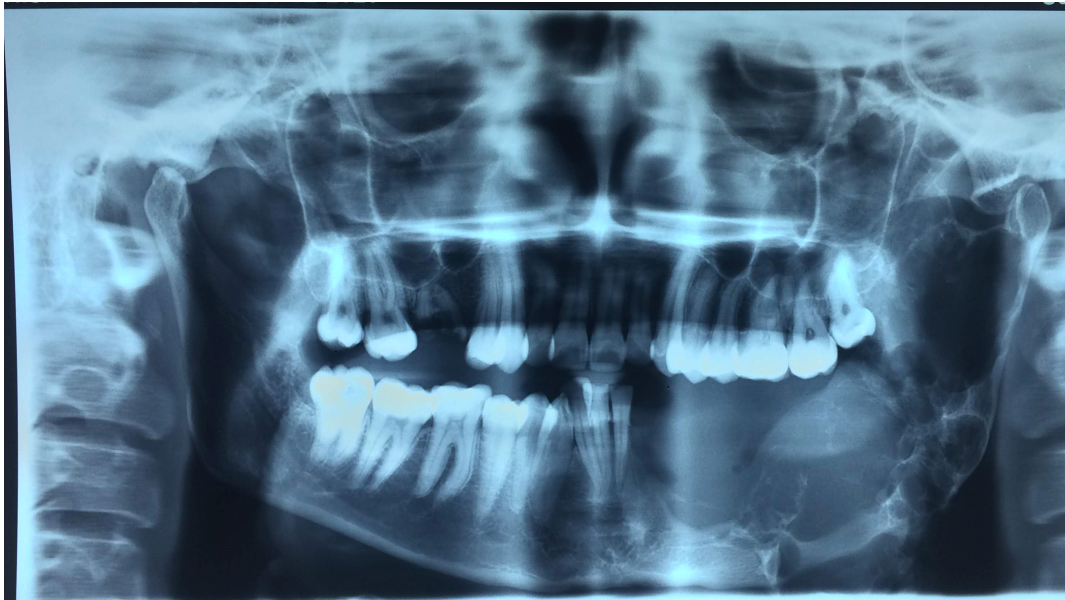
Case scenario

A 27-years-old female reported to maxillofacial OPD with a history of swelling on the lower left side of the face for 5 to 6 years. Her past surgical history revealed that she was operated in Peshawar in March 2018, for curettage and enucleation of the suspected odontogenic cyst. No histopathological diagnosis was provided by the patient. On clinical examination, the swelling was found out to be firm, non-tender, 6x6 cm approximately, with well-defined

borders, extending from left chin to posterior border of mandible obliterating lower border and angle of the mandible. Intraoral examination revealed that her 33 to 38 teeth were missing with the expansion of left buccal and lingual cortical plates. Blood was revealed on aspiration. Her mouth opening was 30 mm, lymph nodes were non-palpable.

The Orthopantomograph (OPG) is shown. Give your differential diagnosis.

What is your diagnosis?



¹Department of Oral Surgery, Abbasi Shaheed Hospital & Karachi Medical & Dental College

²Department of Oral Pathology, Karachi Medical and Dental College

Correspondence: Dr. Sana Iqbal
Department of Oral Surgery, Abbasi Shaheed Hospital
& Karachi Medical & Dental College
Email: s_taurian@hotmail.com

Answer on Page 185