

Pictorial Quiz

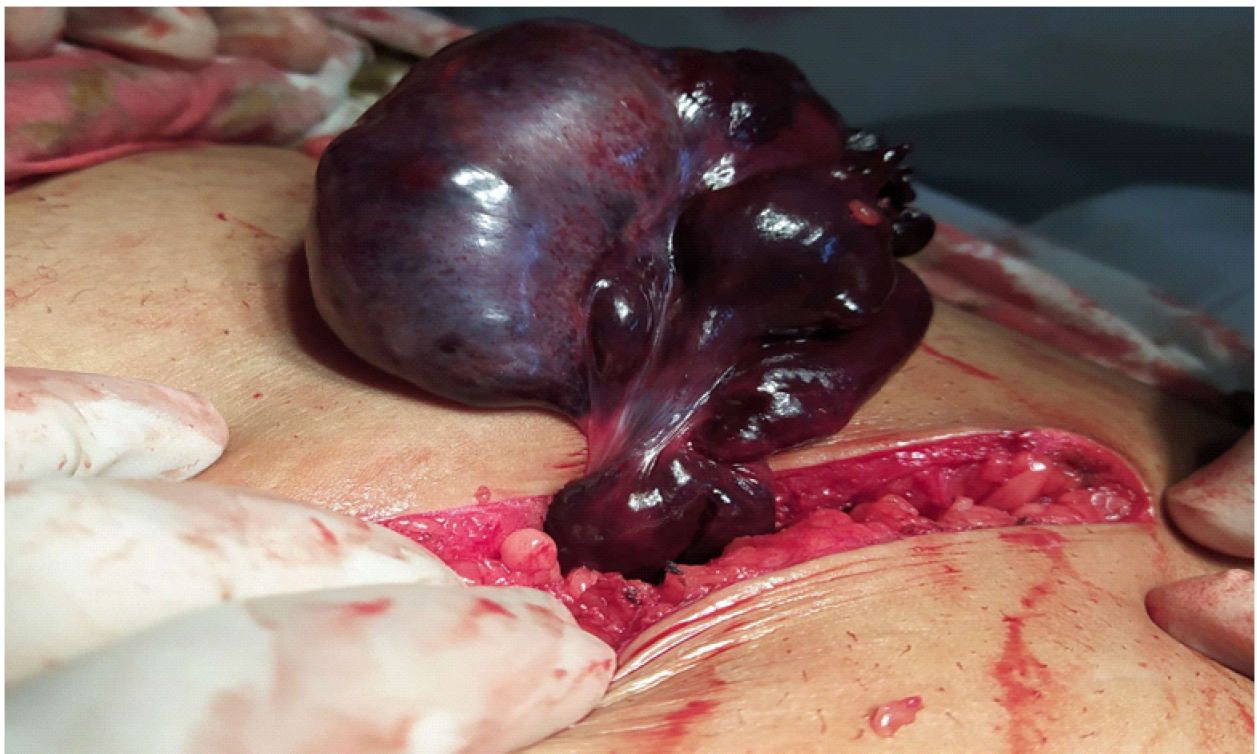
Shameen Shoaib¹, Muhammad Jamaluddin², Sobia Majeed³

Case scenario

An 11-year-old girl came with the complain of colicky right iliac fossa pain for 1 week and vomiting for 1 day. On examination abdomen was soft, tender at right iliac fossa, guarding present all over

the right lower quadrant and rebound tenderness was positive. Digital rectal examination was unremarkable. Ultrasound whole abdomen was normal. Attached below is a picture of the operative findings of the patient.

What is your diagnosis?



Department of Surgery Unit II,
Abbasi Shaheed Hospital, Karachi

Correspondence: Dr. Shameen Shoaib
Department of Surgery Unit II
Abbasi Shaheed Hospital, Karachi
Email: shameenshoaib@yahoo.com
Date of Submission: 14th May 2020
Date of Acceptance: 17th August 2020

Answer on Page 103