

Pictorial Quiz

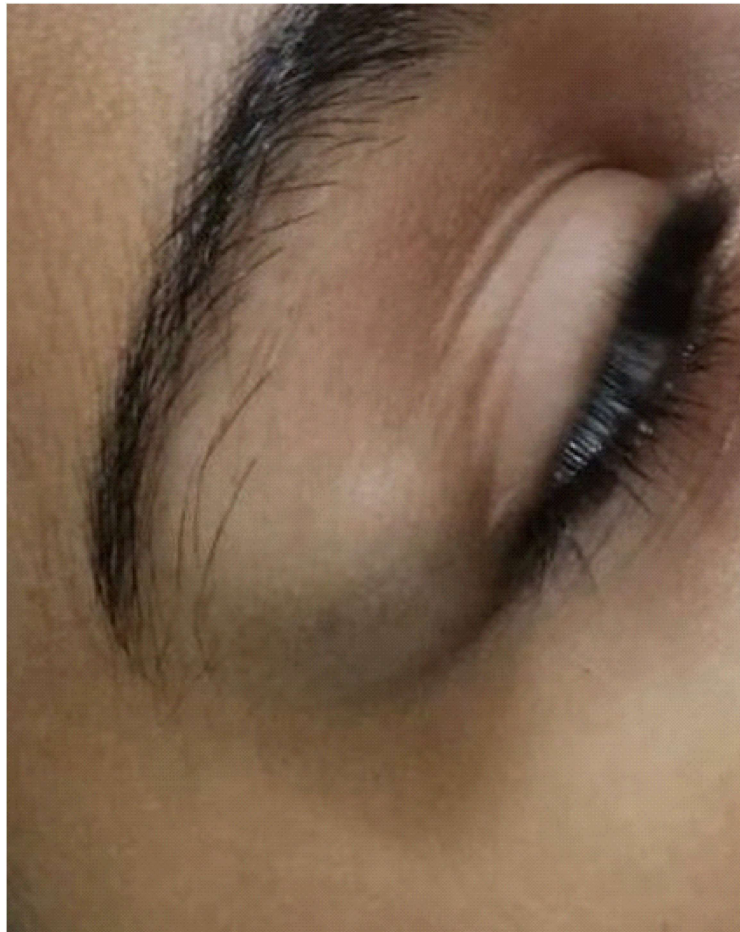
Sobia Majeed¹, Muhammad Jammaluddin²

Case scenario

A 12 year old female child came with c/o swelling at outer canthus of right eye, for 10 years. It does not cause her pain, no discharge and its size remained same.

O/e: swelling is around 1 x 1.5cm, non-tender, round, smooth, margin yield to the pressure and do not slip away, not attached to skin or underlying tissues, cough impulse negative, fluctuation positive but translucency negative. Following is the picture.

What is your diagnosis?



¹⁻²Department of Surgery, Unit-II,
Abbasi Shaheed Hospital, Karachi

Correspondance: Dr. Sobia Majeed
Department of Surgery, Unit-II,
Abbasi Shaheed Hospital, Karachi
Email: dr.sobiamajeed@yahoo.com
Date of Submission: 2nd January 2020
Date of Acceptance: 13th March 2021

Answer on Page 224