

Pictorial Quiz

Wajiha Zia¹, Tahera Ayub²

Case scenario

A 25-years-old male reported to the OPD with the complaint of painless swelling on right side of the mandible for 6 months. On palpation there was a bony-hard, non tender and firm swelling which extends from impacted 3rd from last molar to ramus of the mandible. There was no enlarge lymph

node. OPG shows multilocular radiolucencies on right side of the mandible.

The histological examination of incisional biopsy revealed columnar epithelium with central stellate cells and along with inflammatory cells. There was no evidence of malignancy.

What is your diagnosis?

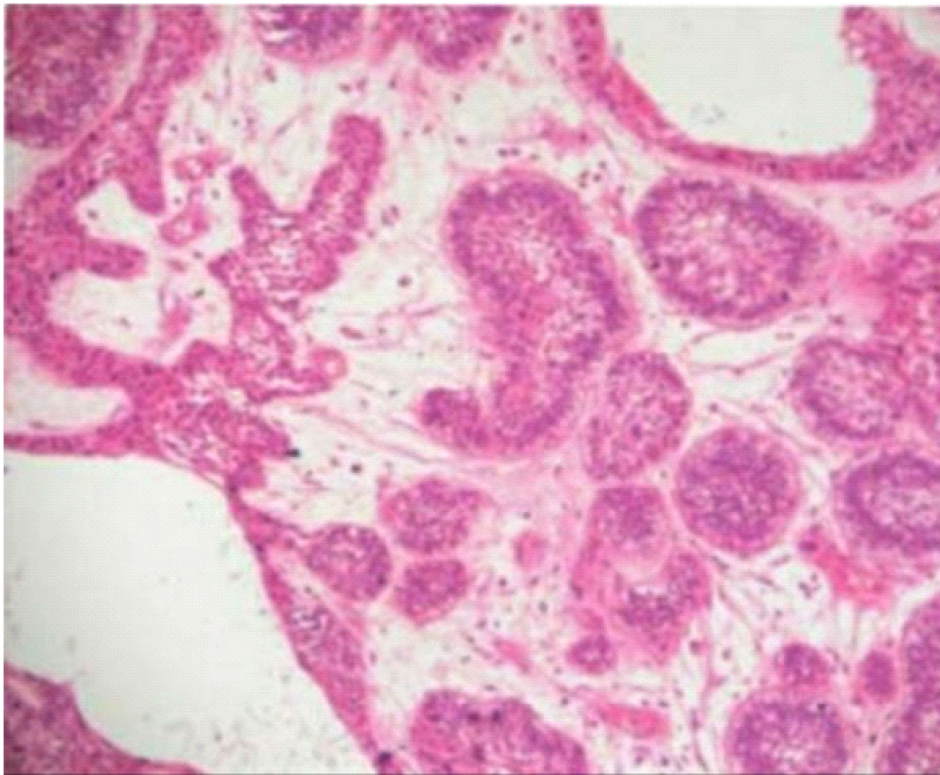


Fig. Histology of incisional biopsy

¹Karachi Medical and Dental College

²Department of Oral Maxillofacial Surgery,
Liaquat College of Medicine and Dentistry

Correspondence: Wajiha Zia
Karachi Medical and Dental College
Email: wajihazia175@gmail.com

Answer on Page 231