

Comparison of Antioxidant Effect of Crocus Sativus and Vitamin E on Amikacin Induced Nephrotoxicity in Albino Rats

Muhammad Kamran¹, Naheed Khan², Hina³, Nasrul Huda⁴, Sadia Iqbal⁵, Ashhad Mazhar Siddiqi⁶

Abstract

Objectives: The present study evaluated the protective effect of Crocus Sativus against Amikacin-induced Nephrotoxicity.

Methods: The prospective descriptive study was conducted at the department of orthopedic surgery, Dr. Ruth KM Pfau Adult laboratory albino rats of the Wistar strain were used in this experimental study. In this study, 75 albino rats were subdivided into 3 groups, including experimental groups B and C. The control group (A) received normal saline intraperitoneally, group (B) received Amikacin 30mg/kg body weight intraperitoneally and Group (C) received Crocus sativus 50 mg/kg body weight orally and vitamin E orally in a dose of 50mg/kg of body weight. Kidneys of rats obtained after dissection were processed, sectioned, and stained in PAS Hematoxylin and Gomoris Methenamine Silver stains. The present study was conducted at Dow University of Health Sciences in the Institute of Biomedical Sciences and Animal House of Dow University and Dow Diagnostic Research and Reference Laboratory. The duration of the study was Three months. Inclusion criteria were Albino rats of both sexes, kidneys of either side (right & left), rats with an approximate weight of 140 to 180 grams were included in the study. Exclusion criteria were overweight rats and pregnant rats.

Results: A significant increase in kidney weight was observed in group B. A considerable addition was observed in proximal tubular in groups B and C. A considerable increase was also observed in the number of intact proximal tubule nuclei and the nuclear diameter of groups B & C.

Conclusion: The study provides evidence that Crocus Sativus has protective effects in Amikacin-induced nephrotoxicity, comparable to widely used Antioxidant Vitamin E. The study recommends the addition of Crocus Sativus in dietary supplements after further evaluation in human subjects.

Keywords: Saffron, Crocus Sativus, Aminoglycosides, Nephrotoxicity, proximal tubules.

IRB: Approved by the Institutional Review Board of Dow University of Health Sciences. Ref# IRB-364/DUHS-2013. Dated: 2nd March 2013.

Citation: Kamran M, Khan N, Hina, Huda N, Iqbal S, Siddiqi AM. Comparison of Antioxidant Effect of Crocus Sativus and Vitamin E on Amikacin Induced Nephrotoxicity in Albino Rats [Online]. Annals ASH & KMDC 2022;27:31-39.

(ASH & KMDC 2022;27:31-39)

Introduction

A massive and growing population in the world uses curative plants and herbs for health care purposes. Therefore, a scientific inspection of the remedial potential of crocus sativus, its biological features, and safety will help make wise decisions about its use. Crocus sativus, also called saffron, has been used as folklore medicine for 4000 years to cure disorders¹.

Crocus sativus is helpful in the treatment of various human diseases in the modern pharmacy and is reported to be an important industrial medical product mainly grown in a cooler region. Saffron is broadly cultivated in different parts of the world like Azerbaijan, Greece, France, Iran, Egypt, Italy, China, Israel, Spain, Morocco, Turkey, Mexico, and Kashmir in India. Pakistan is included in countries with minor production of saffron, where it is cultivated mainly in Baluchistan province².

Crocus sativus is a stemless herb, and it consists of a dried stigma with a small yellowish style. During the last few decades, the chemical mixture of saffron has fascinated several researchers, with about one hundred and fifty volatile and several non-volatile compounds¹.

¹⁻⁶Department of Anatomy, Dow University of Health Sciences

Correspondence: Dr. Muhammad Kamran
Department of Anatomy, Dow University of Health Sciences
Email: muhammad.kamran@duhs.edu.pk
Date of Submission: 1st January 2022
Date of Acceptance: 8th February 2022

Based on available data, it can be stated that saffron contains four main pharmacologically active metabolites; crocin, crocetin, picrocrocin, and safranal which define their worth in the stigma of *Crocus sativus*. Crocin and crocetin are responsible for color, picrocrocin for bitter taste, and safranal for odor and aroma³.

Saffron and its compounds have been used since the past as carminative, diaphoretic, aphrodisiac¹, emmenagogue, and abortifacients. It possesses the properties of being analgesic, euphoriant, and tranquilizer and can alleviate neuralgia, colicky pain, insomnia, depression, etc⁴. A count of studies has proved it to act as antihypertensive, anticonvulsant, antitussive, anxiolytic, and cytotoxic^{1,4}.

Studies have shown that saffron and its compounds have preventive effects on various tissues of the body. Crocin showed high free radical scavenging activity due to its ability to donate a hydrogen atom to free radicals. In a study, Crocin pretreatment increased antioxidant capacity in renal ischemia-reperfusion. The observed preventive effects might be attributed to the decreased malondialdehyde (MDA) levels that correlate with histological and functional data⁵.

Crocetin has been proved to inhibit tumor promotion. It is hepato-protective and also exerts anti-inflammatory effects. Oxidative stress was reported significantly reduced by crocetin in the brain by acting as a scavenger of reactive oxygen species, particularly hydroxyl radical. Crocetin might be able to protect against ROS-related brain diseases such as stroke⁶. Saffron can relieve the deteriorating effects of cisplatin, including the nephrotoxic harm to the kidneys, which is one of its most severe side effects⁷.

Amikacin is one of the most frequently used aminoglycosides, its route of excretion is through the kidneys. The formation and accumulation of reactive oxygen species have been accounted as one of the factors behind its nephrotoxic effect. Reactive oxygen species (ROS) contribute to the destruction of proximal tubular epithelium, apoptotic changes in the kidney, and finally oxidative stress, which ultimately leads to impairment in renal function⁸.

To avoid oxidative stress on the cells and improve tissue defenses, the antioxidant effect of Vitamins is well established. These are safe for oral administration even when ingested in large amounts. One of the essential vitamins for the human body is vitamin E, once considered an anti-sterility agent⁹.

Being fat-soluble and antioxidant, it has a protective role towards cellular integrity. It reduces the lipid peroxidases and free radical injury to the cell membranes providing their stability¹⁰.

Material and Methods

The study aimed to determine the protective effects of *Crocus sativus* on nephrotoxicity and to compare it with the protective effect of vitamin E. The present study was conducted at Animal House. Albino laboratory rats of Wistar strain were used in the present study with weight ranging between 140 to 180 grams and without any sex distinction. These rats were from Charles River Breeding Laboratories, Brooklyn, Massachusetts, U.S.A, and these strains were crossbred at the animal house of Dow University of Health Sciences.

All rats were observed for one week. General health was assessed before the initiation of the study. The rats were lodged in the experiment's room of Animal Sciences Laboratory in labeled plastic cages. They were maintained on a balanced laboratory diet at a temperature of 20-25°C. The current project was commenced after approval from the scientific committee, the ethical committee (IRB). Rats were exposed to drugs for 3 weeks, samples were gathered, fixed, and processed at the end of the 3rd week, microscopy and micrometry were accomplished in two months, and analysis was done in 3 months.

Adult laboratory Albino rats of Wistar strain were used in this experimental study. The rats used belonged to the same age (120 – 140 days) and weight (140 – 180). The sample size was derived after statistical consideration, and a total of forty-five rats were divided into 3 main groups, each with 15 rats for evaluation of variables. The animals were grouped, marked, and kept in separate cages so that each group had 15 rats, and they received treatment for 3 weeks.

The rats were divided into groups as follows:

Groups	Drugs administered	Dose	Route	Duration
A	Normal saline	0.5 -1 cc according to weight	I/P	3 weeks
B	Amikacin	30mg/kg	I/P	2 weeks from day 6 onward
C	Crocus Sativus + Vitamin E	50mg/kg 30mg/kg	Oral I/P	3 weeks 2 weeks from day 6 onward

The liquid solution of Crocus sativus was prepared by dissolving it in distilled water. It was administered orally with a feeding tube in a dose calculated according to body weight.

The rats were weighed as the experiment commenced and ended, sacrificed after being anesthetized by Ether. An incision was given in the abdomen at a mid-sagittal plane to expose the kidneys. Both the kidneys were mobilized and dissected out. The weight of each kidney was measured before being examined for gross morphology. This was followed by incising the kidneys longitudinally and fixing them in 10% buffered formalin.

Kidneys were kept in 10% formalin for fixation for the next 1-2 days. The tissues were dehydrated from 70% to 100% by using ascending strengths of alcohol and cleared in xylene and embedding in paraffin to obtain blocks for sectioning. Sections with a thickness of five microns were cut on a rotary microtome and were mounted on clean, properly labeled glass slides. The slide's labeling was done using a diamond pencil, and for the next 24 hours, to fix the sections on the slides, it was placed at 37°C on the hotplate. The slides were stained using Periodic Acid Schiff (PAS) Hematoxylin stain and Gomori Methenamine Silver stains (GMS).

Light microscopic study of PAS stained sections was done in detail. Different variables were studied using the ocular and stage micrometer under 40X and 100X oil immersion objectives. The PAS stain was used for the study to get clear boundaries of proximal convoluted tubules, as brush border and basement membranes were visualized.

Moreover, cell membranes were visualized to some extent. On 40X objective proximal convoluted tubular count was done in randomly selected five HPF of cortical region of each kidney. On 100X oil immersion, the objective nuclear count was done, and nuclear diameter was measured.

GMS (Gomori Methenamine Silver) stain was also used to stain slides to visualize the basement membrane and brush border clearly.

Variables of the study were: gross variables control and exposed/experimental groups (Initial and final weight), kidney weight, the gross appearance of dissected tissue, including consistency, shape, size, contour, discoloration, edema, hemorrhage.

Microscopic variables were the renal tubules and glomeruli having a regular outline, absence of epithelial and nuclear debris in the lumen was considered normal.

Qualitative variables were cytoplasmic alterations such as necrosis, the occurrence of vacuoles or features other than normally observed in the cells, any change in staining intensity, nuclear shape, and position were noted, the brush border and tubular basement membrane of the proximal convoluted tubule (PCT) were observed for any damage, presence of epithelial cast or debris in lumina of proximal tubule was noted. Quantitative variables were the number of proximal tubules was counted under 10X ocular and 40X objectives, in randomly selected five high power fields (HPF), the PCT nuclear count was completed under 10X ocular lens and 100X objective, in randomly selected five high power fields (HPF), Nuclear diameter of randomly selected 20 nuclei/HPF in five different fields of renal cortices was measured, using 10X ocular and 100X oil immersion objective.

Data were recorded and analyzed using Statistical Package for Social Sciences (version 23.0). Mean, and standard deviation was obtained for all parameters. Paired sample t-test was used to compare the mean difference in weight at the initial and final stages. One-way analysis of variance (ANOVA) F-test was used to compare the mean level across all five groups. Further

post hoc analysis of significant results obtained from ANOVA was accessed using Tukey HSD test between groups for the multiple comparisons. All p-values less than 0.05 were considered statistically significant. Bar charts were used to give the graphical presentation of the results.

Results

After sacrificing the animals, obtaining samples, and after due lab work and slide preparations, histomorphological assessments were done, and results of the observation were obtained through biostatistical analysis given as under.

The mean \pm standard deviation of the initial weight of albino rats in different groups, measured before the treatment were 167.60 ± 7.49 in group A, 168.08 ± 8.08 in group B, and 166.93 ± 8.92 in group C. The mean weight and standard deviation of the final weight of albino rats in different groups measured after the treatment were 171.07 ± 2.57 in group A, 175.07 ± 2.31 group Band 170.8 ± 2.80 in group C. The mean \pm standard deviation of the weight of kidney in different groups measured were 0.61 ± 0.05 in group A, 0.64 ± 0.02 in group B, and 0.51 ± 0.04 in group C respectively. When comparing the group's p-value is less than 0.01, which is highly significant (Table 1).

Table 1: Comparison of weight (gm) of Kidneys of Albino rats.

Weight of Kidney Tukey HSD						
(I) Group	(J) Group	Mean Difference (I-J)	Standard Error	p-value	95% Confidence Interval	
					Lower Bound	Upper Bound
Group A (n=15)	Group B (n=15)	-0.02467	0.01651	0.57	-0.0709	0.0216
	Group C (n=15)	.10400*	0.01651	<0.01*	0.0578	0.1502
Group B (n=15)	Group A (n=15)	0.02467	0.01651	0.57	-0.0216	0.0709
	Group C (n=15)	.12867*	0.01651	<0.01*	0.0824	0.1749
Group C (n=15)	Group A (n=15)	-.10400*	0.01651	<0.01*	-0.1502	-0.0578
	Group B (n=15)	-.12867*	0.01651	<0.01*	-0.1749	-0.0824

*. The mean difference is significant at the 0.05 level.

The proximal convoluted tubules with regular outlines and intact basement membrane were counted in 5 HPF of the cortical region. The mean \pm standard deviation numbers of intact proximal tubules in different groups

measured were 55.93 ± 7.51 in group A, 56.80 ± 8.01 in group B, and 53.77 ± 7.48 in group C respectively. When comparing the group's p-value is less than 0.01, which is highly significant (Table 2).

Table 2: Mean Comparison of Number of Intact Nuclei of Proximal Tubules in Cortical region of Albino rats in different groups.

Groups		Mean Difference	Standard Error	p-value	95% Confidence Interval	
					Lower Bound	Upper Bound
Group A (n=15)	Group B (n=15)	-0.867	2.73	0.998	-8.51	6.78
	Group C (n=15)	2.167	2.73	0.932	-5.48	9.81
Group B (n=15)	Group A (n=15)	0.867	2.73	0.998	-6.78	8.51
	Group C (n=15)	3.033	2.73	0.8	-4.61	10.68
Group C (n=15)	Group A (n=15)	-2.167	2.73	0.932	-9.81	5.48
	Group D (n=15)	-3.033	2.73	0.8	-10.68	4.61

*. The mean difference is significant at the 0.05 level.

The number of intact nuclei of proximal tubules in 5 HPF of the cortical region was counted. The mean ± standard deviation of several intact nuclei of proximal tubules in different groups measured were 22.53 ± 9.47 in group A, 23.47 ± 1.55 in group B, and 17.60 ± 2.61 in group C, respectively. When comparing the group's p-value is less than 0.01, which is highly significant

(Table 3). When multiple comparisons were made, the difference in the number of intact nuclei of proximal tubules in B and C (p-value ≤ 0.01) was significant. The difference in the number of intact nuclei of proximal tubules between groups A and B (p-value = 0.982) showed an insignificant change.

Table 3: Mean Comparison of Number of Intact Nuclei of Proximal Tubules in Cortical region of Albino rats in different groups.

Multiple Comparisons						
Number of Intact Nuclei of Proximal Tubule's in Cortical Region of Kidney of Albino Rats						
Tukey HSD						
(I) Group	(J) Group	Mean Difference (I-J)	Standard Error	p-value	95% Confidence Interval	
					Lower Bound	Upper Bound
Group A (n=15)	Group B (n=15)	-0.933	1.695	0.982	-5.68	3.81
	Group C (n=15)	4.933*	1.695	.038*	0.19	9.68
Group B (n=15)	Group A (n=15)	0.933	1.695	0.982	-3.81	5.68
	Group C (n=15)	5.867*	1.695	<0.01*	1.12	10.61
Group C (n=15)	Group A (n=15)	-4.933*	1.695	.038*	-9.68	-0.19
	Group D (n=15)	-5.867*	1.695	<0.01*	-10.61	-1.12

*. The mean difference is significant at the 0.05 level.

The nuclear diameter of proximal convoluted tubular cells in different groups was compared. (Table 4). The mean ± standard deviation of nuclear diameter of proximal convoluted tubular cells in different groups

measured were 13.920 ± 1.4775 in group A, 13.200 ± 1.4298 in group B, and 11.867 ± 1.9952 in group C, respectively. When comparing the group's p-value is less than 0.01, which is highly significant.

Table 4: Mean Comparison of Nuclear Diameter of Proximal Convoluted Tubular Cell of Kidney of Albino rats in different groups.

Multiple Comparisons						
Nuclear Diameter of PCT Cells of Kidney of Albino Rats						
Tukey HSD						
(I) Group	(J) Group	Mean Difference (I-J)	Standard Error	p-value	95% Confidence Interval	
					Lower Bound	Upper Bound
Group A (n=15)	Group B (n=15)	0.72	0.5969	0.748	-0.951	2.391
	Group C (n=15)	2.0533*	0.5969	<0.01*	0.382	3.725
Group B (n=15)	Group A (n=15)	-0.72	0.5969	0.748	-2.391	0.951
	Group C (n=15)	1.3333	0.5969	0.18	-0.338	3.005
Group C (n=15)	Group A (n=15)	-2.0533*	0.5969	<0.01*	-3.725	-0.382
	Group B (n=15)	-1.3333	0.5969	0.18	-3.005	0.338

*. The mean difference is significant at the 0.05 level.

The histological study of Periodic Schiff-Haematoxylin stained sections of renal cortical tissue was done in detail. Control group A revealed a well-defined cortex and medulla of renal tissue with a regular arrangement of urinary tubules and Malpighian corpuscles. There were well-organized areas of cortical labyrinths

alternating with medullary rays. A thorough study of proximal convoluted tubules under the light microscope showed that they were tightly packed appeared oval, circular, or elliptical in outline owing to cutting in various directions. The tubules were mostly found in the vicinity of glomeruli within the cortex.

The lining epithelial cells of proximal convoluted tubules were low columnar, found regularly organized on an intact and well-demarcated basement membrane (Figure 1). The tubular cells showed spherical nuclei positioned centrally or basally. Cytoplasm appeared fine and granular with no degenerative, necrotic, or adaptive changes in the proximal tubular epithelial cells (Figure 2). A regular and distinct brush border was found on the luminal surface of proximal tubular epithelial cells, while the lumina themselves were freed of any cellular or nuclear debris. Most of the cells presented nuclei with evenly distributed fine and regular chromatin. Also, nucleoli were observed in many of these nuclei (Figure 2).

The morphological observation of PAS-stained sections of groups B and C kidneys showed normal cortical architecture (Figure 3) with well-defined cortical labyrinths and medullary rays. The epithelium of PCT appeared low columnar, with sufficient and granular cytoplasm. No necrotic or degenerative alterations in cellular lining were observed. The epithelial cells were arranged regularly on a well-defined, intact basement membrane, while the brush border on the luminal surface of epithelial cells was distinct and regular (Figure 3). The proximal tubular lumina were without any cellular and nuclear debris. A great number of proximal tubular cells showed nuclei with prominent nucleoli and evenly distributed, fine and regular chromatin (Figure 3).

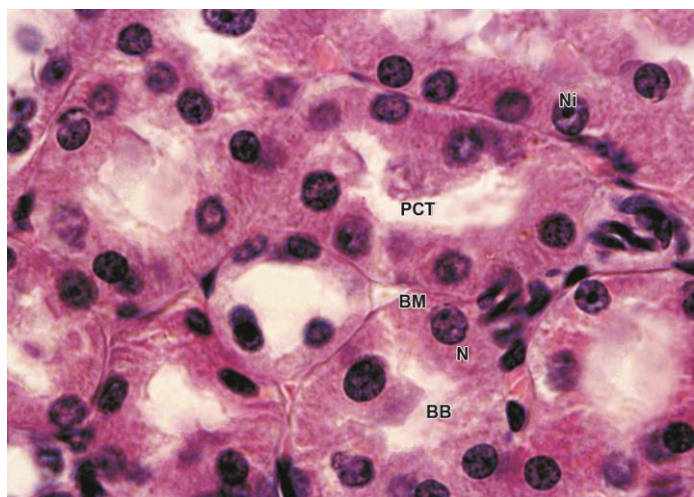


Figure 1: Photomicrograph of 5µm thick L.S of Kidney of group A, stained with PAS and Haematoxylin, showing PCT with intact brush border (BB), basement membrane (BM), Nuclei (N) and Nucleoli (Ni), X100

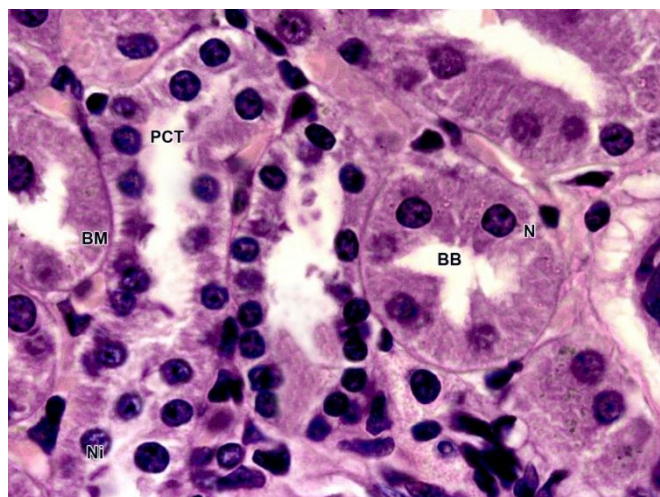


Figure 2: Photomicrograph of 5µm thick L.S of Kidney of group B stained with PAS and Haematoxylin, showing PCT with intact brush border (BB) basement membrane (BM), Nuclei (N) and Nucleoli (Ni), X100

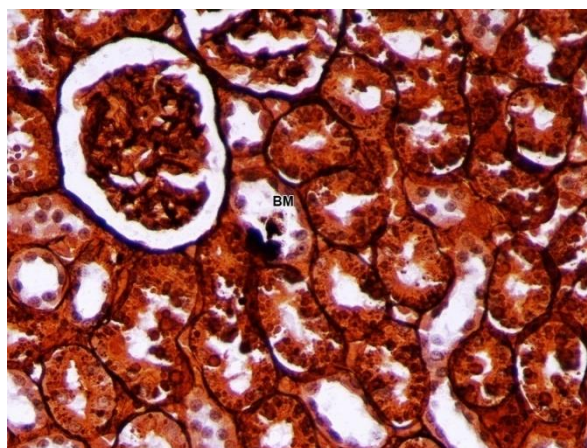


Figure 3: Photomicrograph of 5µm thick L-S of Kidney of group A stained with Gomori's Mathenamine Silver, showing well defined and regular basement membrane (BM) lining the PCT, 400X

Discussion

The project was designed to study the protective effect of Crocus Sativus and compare its ameliorating effect with the antioxidant vitamin E. The kidneys of the controls and the exposed animals were dissected out, and after recording their weights, they were processed and stained for light microscopic study.

The comparison of initial and final weights of animals was made. The final weights were increased insignificantly in control group A and group C. A significant increase in final weight was observed in group B. It showed that saffron extract increased the body weight in a dose-dependent manner¹¹. That saffron could improve the body weight in diabetic rats¹². A significant increase in body weight was observed on oral administration of different doses of saffron extract. This is probably due to the effects of saffron in reducing anorexic time¹³. Saffron ameliorates Amikacin's effects by reducing oxidative stress and cellular damage¹⁴.

When the weight of kidneys at the end of the experimental period was measured, a significant decrease was observed in groups C compared to their corresponding control. Our findings are comparable to a study in which gentamicin produced statistically significant body and kidney weight loss due to anorexia and partial renal failure leading to acidosis¹⁵. The weight of group B was significantly increased compared to group A and group C. The findings are in accord with the researcher, which showed that crocin treatment had a slight increment of liver weight¹⁶. In group, C kidney weight was reduced when compared to all the other groups.

The tubular toxicity of Amikacin causes the death of proximal tubular epithelial cells by bringing about a functional change of important cellular components, particularly those involved in the transport of water and solute¹⁷. The aminoglycoside nephrotoxicity results from tubular cytotoxicity that results in necrosis and cell death or apoptosis. The cytotoxicity is attributed to inhibition of cellular respiration at the mitochondrial level, depletion of cellular ATP reserves, and oxidative stress by increasing superoxide anions and hydroxyl radicals, contributing to cell death¹⁸.

Amikacin acts by binding with membrane phospholipids, thereby altering their turnover and metabolism. Consequently, it causes a condition known as phospholipidosis, which directly correlates with the level of toxicity of aminoglycosides¹⁹.

Furthermore, inhibition of various cell membrane transporters, including Na-K adenosine triphosphatase of both the brush-border and the basolateral membrane, occur²⁰ affecting tubular reabsorption, altered cellular homeostasis, and deregulated swelling that may lead to necrosis or apoptosis²¹.

An insignificant increase was observed in group B in comparison to group A. Our findings are comparable to a study²². MDA levels, an indicator of lipid peroxidation, were lowered in renal tissue of rats receiving an aqueous extract of saffron. Because of this change in lipid peroxidation and a consequent decrease in ROS production, the number of intact proximal tubules is improved compared to B group rats treated with Crocus Sativus²³. Moreover, Crocus Sativus has vasodilator effects increasing renal blood flow²⁴.

The number of nuclei was decreased in all the Amikacin treated groups, which might be due to the release of contents of cytoplasm and nuclei from the distorted apical surface of tubular epithelial cells. Moreover, many shrunken nuclei were observed due to degenerative changes as were observed in nephrotoxicity induced by lead²⁵. The study recommends the addition of Crocus Sativus in dietary supplements after further evaluation in human subjects.

Conclusion

The present study provides the evidence that Crocus Sativus including crocin, crocetin and picrocrocins have protective effects in Amikacin induced nephrotoxicity. The present study shows that Crocus Sativus, including crocin, crocetin, and picrocrocins, have protective effects in Amikacin-induced nephrotoxicity. The effects of Crocus Sativus are comparable to widely used Antioxidant Vitamin E. The effects of Crocus Sativus are comparable to widely used Antioxidant Vitamin E.

Conflict of Interest

Authors have no conflict of interest and no grant/funding from any organization.

References

1. Srivastava R, Ahmed H, Dixit RK. Crocus sativus L.: a comprehensive review. *Pharmacogn Rev.* 2010;4(8):200.
2. Husaini AM, Kamili AN, Wani MH, Teixeira da Silva JA, Bhat GN. Sustainable saffron (*Crocus sativus* Kashmirianus) production: technological and policy interventions for Kashmir. *Funct. Plant Biol.* 2010;4(2):116-27.
3. Hosseinzadeh H, Karimi G, Niapoor M. Antidepressant effect of *Crocus sativus* L. stigma extracts and their constituents, crocin and safranal, in mice. In *International Symposium on Saffron Biology and Biotechnology 650 2003*. pp. 435-445.
4. Kumar V, Bhat ZA, Kumar D, Khan NA, Chashoo IA, Shah MY. Pharmacological profile of *Crocus sativus*—a comprehensive review. *Pharmacologyonline.* 2011;3:799-811.
5. Hosseinzadeh H, Ziaee T, Sadeghi A. The effect of saffron, *Crocus sativus* stigma, extract and its constituents, safranal and crocin on sexual behaviors in normal male rats. *Phytomedicine.* 2008;15(6-7):491-5.
6. Shen XC, LU Y, Qian ZY. Effects of crocetin on the matrix metalloproteinases in cardiac hypertrophy induced by norepinephrine in rats. *J Asian Nat Prod Res.* 2006;8(3):201-8.
7. Pabla N, Dong Z. Cisplatin nephrotoxicity: mechanisms and renoprotective strategies. *KI.* 2008;73(9):994-1007.
8. Kędziora-Kornatowska K, Szram S, Kornatowski T, Szadujkis-Szadurski L, Kędziora J, Bartosz G. Effect of vitamin E and vitamin C supplementation on antioxidative state and renal glomerular basement membrane thickness in diabetic kidney. *Nephron Exp Nephrol.* 2003;95(4):e134-43.
9. Al-Attar AM. Antioxidant effect of vitamin E treatment on some heavy metals-induced renal and testicular injuries in male mice. *Saudi J Biol Sci.* 2011;18(1):63-72.
10. Amjad Z, Shabbir S, Mughal A, Zeb T, Amin R, Mirza T. Effect of Ginkgo Biloba Extract (EGb 761) on Lead-induced Nephrotoxicity in Wistar Albino Rats. *IJEHSR.* 2020;8(4):202-211.
11. Samarghandian S, Azimi-Nezhad M, Samini F. Ameliorative effect of saffron aqueous extract on hyperglycemia, hyperlipidemia, and oxidative stress on diabetic encephalopathy in streptozotocin induced experimental diabetes mellitus. *Biomed Res Int.* 2014;2014.
12. Farkhondeh T, Samarghandian S. The effect of saffron (*Crocus sativus* L.) and its ingredients on the management of diabetes mellitus and dislipidemia. *Afr J Pharmacy Pharmacol.* 2014;8(20):541-9.
13. Alonso GI, Salinas Mr, Garijo J, Sánchez-Fernández Ma. Composition of crocins and picrocrocins from Spanish saffron (*Crocus sativus* L.). *J Food Qual.* 2001;24(3):219-33.
14. Al-Snafi AE. The pharmacology of *Crocus sativus*-A review. *IOSR J Pharm.* 2016;6(6):8-38.
15. Halataei BA, Khosravi M, Arbabian S, Sahraei H, Golmanesh L, Zardooz H, Jalili C, Ghoshooni H. Saffron (*Crocus sativus*) aqueous extract and its constituent crocin reduces stress-induced anorexia in mice. *Phytother Res.* 2011;25(12):1833-8.
16. Hariri AT, Moallem SA, Mahmoudi M, Hosseinzadeh H. The effect of crocin and safranal, constituents of saffron, against subacute effect of diazinon on hematological and genotoxicity indices in rats. *Phytomedicine.* 2011;18(6):499-504.
17. Mashmoul M, Azlan A, Mohtarrudin N, Mohd Yusof BN, Khaza'ai H, Khoo HE, Farzadnia M, Boroushaki MT. Protective effects of saffron extract and crocin supplementation on fatty liver tissue of high-fat diet-induced obese rats. *BMC Complement Altern Med.* 2016;16(1):1-7.
18. Akinbodewa AA, Okunola O. Concomitant gentamicin-induced nephrotoxicity and bilateral ototoxicity. *Niger J Clin Pract.* 2016;19(4):563-6.
19. Wargo KA, Edwards JD. Aminoglycoside-induced nephrotoxicity. *J Pharm Pract.* 2014;27(6):573-7.
20. Cuzzocrea S, Mazzon E, Dugo L, Serraino I, Di Paola R, Britti D, De Sarro A, Pierpaoli S, Caputi AP, Masini E, Salvemini D. A role for superoxide in gentamicin-mediated nephropathy in rats. *Eur J Pharmacol.* 2002;450(1):67-76.
21. Sassen MC, Kim SW, Kwon TH, Knepper MA, Miller RT, Frøkiaer J, Nielsen S. Dysregulation of renal sodium transporters in gentamicin-treated rats. *KI.* 2006;70(6):1026-37.
22. Bonegio R, Lieberthal W. Role of apoptosis in the pathogenesis of acute renal failure. *Curr opin nephrol hypertens.* 2002;11(3):301-8.
23. Lieske J, De La Vega LP, Slezak JM, Bergstralh EJ, Leibson CL, Ho KL, Gettman MT. Renal stone epidemiology in Rochester, Minnesota: an update. *KI.* 2006;69(4):760-4.
24. Martinez-Salgado C, López-Hernández FJ, López-Novoa JM. Glomerular nephrotoxicity of aminoglycosides. *Toxicol Appl Pharmacol.* 2007;223(1):86-98.
25. Khan NA, Naqvi AN, Perveen KH, Rafique MU. Lead

induced nephrotoxicity with special reference to proximal tubule in albino rats. Pak J Pharm Sci. 2008;25:29-35.