

A Case Report on Recurrent Dermatofibrosarcoma protuberans (DFSP), Successful Surgical Excision is Treatment of Choice

Arshadullah Khan¹, Sumayya Tajwar²

Abstract

A 23-years-old male patient came to the Surgical Oncology clinic in Saudi National Hospital, Makkah with complaint of non-healing wound present on the medial side of the right thigh since three months. A detailed history was taken and it was revealed that this was a fast growing lesion and recurred immediately after surgical excision. The previous surgery had been carried out three months back in India. On the clinical examination it was revealed that it was an irregular, ill-defined lesion, hard in consistency, not adherent to the underlying structures, and hence highly suspicious of malignancy. Diagnostic workups were done including biopsy, metastatic workup including computer tomography (CT) scan chest abdomen and pelvis. On the basis of histopathology, it was diagnosed as dermatofibrosarcoma protuberans (DFSP). The case was presented in the Sarcoma Tumour Board and according to Tumour Board's recommendation, surgical excision was conducted. Patient was sent for anaesthesia assessment and after complete blood workup, and pre-anaesthesia assessment, patient was booked for elective resection of tumour. The tumour was successfully excised with all negative margins confirmed on the frozen section and finally the sample was sent for histopathology. Post-excision, patient was followed in surgical oncology clinic for local and systemic recurrence and it was concluded after three years follow-up, that there was no local and systemic recurrence. The dermatofibrosarcoma has high potential for local recurrence and surgical excision with 2 cm negative margins is the treatment of choice without adjuvant radiotherapy.

Keywords: dermatofibrosarcoma, local neoplasm recurrence, margins of excision.

Citation: Khan A, Tajwar S. A Case Report on Recurrent Dermatofibrosarcoma protuberans Successfully Surgical Excision is Treatment of Choice [Online]. Annals ASH KM&DC 2018;23.

(ASH & KMDC 23(1):191;2018)

Introduction

Dermatofibrosarcoma protuberans (DFSP) is a rare type of cancer, a soft tissue sarcoma that develops in the deep layers of skin. It is sometimes described as having tentacles that can grow into surrounding fat, muscle and even bone. Dermatofibrosarcoma is low to medium grade, rare tumour of the skin having recurrence potential due to incomplete excision of tumor¹. It is slow growing malig-

nant mesenchymal tumour of the dermis. The distinct metastasis is less likely to occur but in some cases, it commonly metastasises to lung and regional lymph nodes. The treatment of choice is surgical excision with all negative margin followed by radiotherapy. The rationale of this case report is that this is one of the rare dermatological tumours having high potential of recurrence; and surgical excision with negative margins is the treatment of choice.

Case Report

A 23-year-old Indian male was referred from local polyclinic to Saudi National Hospital Makkah Saudi Arabia with history of non-healing wound as per patient opinion. It was a recurrent swelling present at medial side of the thigh. He had history

¹ Department of surgical Oncology,

² Department of Anaesthesia,
King Abdul Aziz Medical City, Jeddah Saudi Arabia

Correspondence Arshadullah Khan
Department of Surgical Oncology
King Abdul Aziz Medical City, Jeddah Saudi Arabia
Email: drarshadpk@hotmail.com
Date of Submission: 12th January 2018
Date of Acceptance: 27th February 2018

of surgical excision of lump three months ago. Patient's permission was taken for writing this case report and for the picture printed in this publication.

On the clinical examination, it was 2x2 cm swelling present over the surgical scar present at medial side of the thigh, reddish brown colour with black patches over the swelling, mobile and not adhered to the underlying structure. There was no pain and tenderness present over the swelling, Fig. 1.

After initial assessment, the swelling underwent biopsy and it was diagnosed as dermatofibrosarcoma. After initial diagnosis, metastatic work up was conducted, including CT scan, chest, abdomen and pelvis revealed that it was negative for distinct metastasis. The case was presented in the tumour board and the recommendation of tumour board was surgical excision, Fig. 2. Patient underwent wide local surgical excision with 2 cm safety margin, performed under general anaesthesia and the specimen were sent to final histopathological assessment. The specimen contained deep fascia, and some part of the muscles. Finally, histopathological examination of resected specimen revealed characteristic cartwheel appearance confirming the diagnosis of the dermatofibrosarcoma protuberans (DFSP), Fig 3.

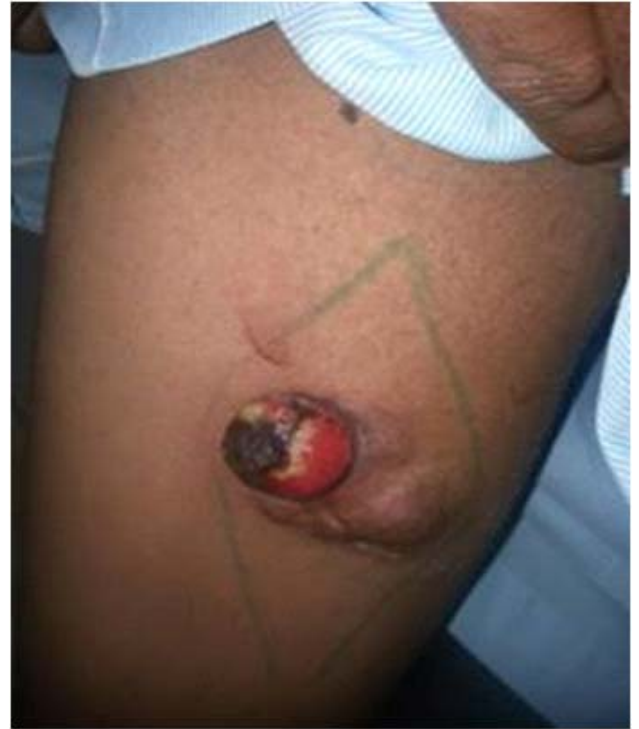

Fig 1. About 2.0x2.0 cm irregular erythematous-violaceous lesion showing an atrophic change with a scar tissue in the central portion on the medial region of the right thigh. An area in the Lesion shows a reddish brown in color

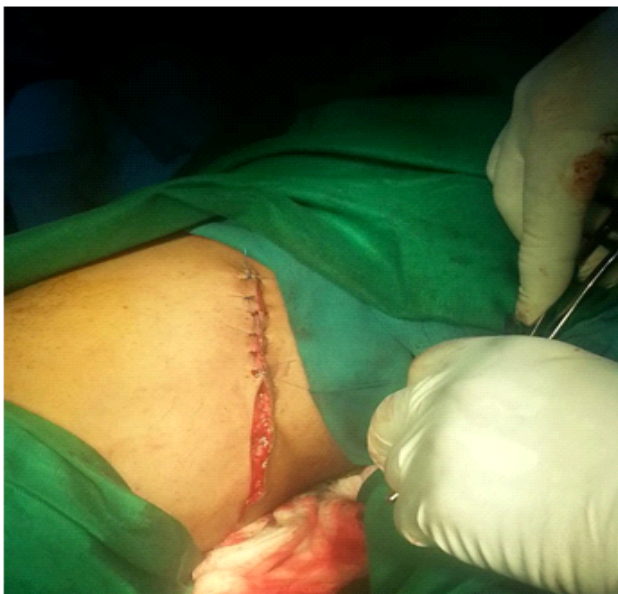

Fig. 2. Post-local wide excision and closure of the wound

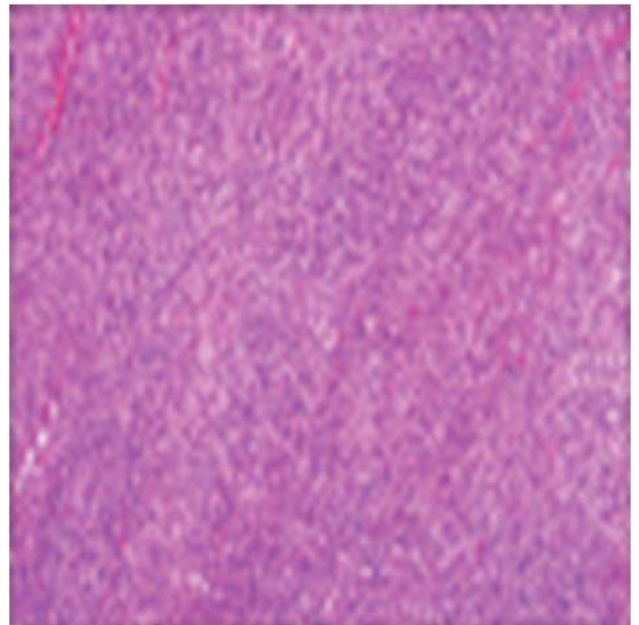


Fig. 3. The histopathology confirmed DFSP with clear margins

Post excision, patient was followed in surgical oncology clinic for local and systemic recurrence and it was concluded that after three years of follow-up did not identify local and systemic recurrence. The histopathology confirmed DFSP with clear margins. There was no evidence of recurrence after 3 years.

Discussion

DFSP is a kind of mesenchymal tumour of the skin with high potential of local recurrence. It is a locally aggressive tumour and arises from the dermatological origin. It is a kind of sarcoma with less than 0.1% of all malignancies and to approximately 1% of the all soft tissue sarcoma with an annual incidence of 0.8 to 4.5 cases per million individual¹⁻⁸.

The common site is trunk and lower limbs, but it is unusual in above neck and breast region⁵. Taib et al. have described a case of a large fungating infantile dermatofibrosarcoma of the penis in a two-year-old Malay boy⁴.

The ratio between male and female is 1:1, however it is reported a slight predominance in male. It is presented as asymptomatic, multinodular bluish, brownish, erythematous lesion growing slowly over the years. Skin is fixed to tumour, but underlying muscles are free of tumour as described in our case. CT and MRI may be sometimes needed to look for the deeper extent of the tumour, but in our case, the diagnosis was revealed by fine needle aspiration (FNA) and confirmed after histopathological examination of resected specimen, it's typical protuberant aspect is the most frequently observed clinical aspect¹⁻⁹. Cartwheel appearance is characteristic of DFSP on microscopy as was found in our case also⁵. CD34 is a highly specific tumour marker for diagnosis of DFSP⁶.

In general, the tumour is located in the dermis, but it can sometimes present infiltrative growth in the subcutaneous fatty tissue, forming a pastry pattern (60% of cases; neoplastic cell bands parallel to the epidermis) or a honeycomb pattern (delimitation of adipocyte islets between the tumour tissue)^{3,9}.

Dermatofibrosarcoma protuberans (DFSP) is characterised by its aggressive local invasion. The tumour invades local tissue by extending tentacle like projections underneath healthy skin, rendering complete removal of the tumour very difficult. Incomplete removal of these neoplastic cells results in a high local recurrence rate.

Its low potential for metastasis is typical, with less than 5% probability for regional or distant metastases, with these often being restricted to the lungs and less frequently to the lymph nodes^{8,10-11}.

As far as the treatment of the DFSP is concerned, the standard care is the wide local excision with 2-3 cm tumour free margins and three-dimensional resection including skin, subcutaneous tissue and under lying fascia⁸ and local recurrence can decrease with wide surgical margins.

The factors associated with high rates of recurrence are histological subtype, cellularity, size, location on the head and neck, and high mitotic rate¹¹. Histologic features of DFSP may also serve as prognostic indicators. A high number of mitotic figures, increased cellularity, DNA aneuploidy, TP53 gene overexpression, and the presence of fibrosarcomatous changes within the tumour are poor prognostic indicators. Of note here is the fact that, fibrosarcomatous variants of DFSP lacking a genetic marker of translocation between chromosomes 17 and 22 may not respond to imatinib. The loss of the t(17,22) cytogenetic marker in the fibrosarcomatous progression DFSP variant may represent progression of the malignancy.

Local recurrence rate of 20-50% is reported in cases with incomplete resection. Patients with unresectable or positive margins should be treated with adjuvant radiotherapy to decrease the recurrence rate. It reduces the local recurrence rate^{12,13}. Recurrent lesion can be treated either with re-excision, radiotherapy, or both. Imatinib mesylate, a drug used in chronic myelogenous leukaemia, has been successful in metastatic disease and/or relapses of the entity¹¹.

Imatinib is currently considered the gold standard in the treatment of inoperable and/or metastatic and/or recurrent cases of DFSP. Therapy with imatinib may potentially facilitate resection or decrease possible disfigurement related to radical surgical procedure³. However, in our case, histopathology of excised specimen had negative margins, so our case did not receive any adjuvant therapy.

Radiation therapy is an adjuvant therapy in cases where adequate surgical margins are not easily reached or result in aesthetic/functional defect, or in cases of positive margins, even after maximum resection. It is also indicated for patients with inoperable macroscopic lesions¹⁻⁷.

Postoperative radiotherapy has been associated with a cure rate of more than 85%¹³. However, it presents risks such as acute or chronic radio dermatitis and subsequent development of other skin tumors¹.

The local recurrence may occur late in 24-90% cases and mostly appear with 3 years and half occur in the first year after excision.

Conclusion

Wide radical excision is the preferred surgical method for therapy of DFSP in case of local recurrence.

Conflict of Interest

Authors have no conflict of interests and no grant/funding from any organisation.

Reference

- Bhambri S, Desai A, DelRosso JQ, Mobini N: Dermatofibrosarcoma protuberans: a case report and review of the literature. *J Clin Aesthet Dermatol* 2008;1:34-36. Available from: https://www.ncbi.nlm.nih.gov/pmc/articles/PMC2989807/pdf/jcad_1_1_34.pdf. Accessed on February 2018.
- Hong YJ, Choi HY, Myung KB, Choi HY. A case of myxoiddermatofibrosarcoma protuberans. *Ann Dermatol* 2011;23:379-381. [DOI:10.5021/ad.2011.23.3.379].
- Rutkowski P, Wozniak A, Switaj T. Advances in molecular characterization and targeted therapy in dermatofibrosarcoma protuberans. *Sarcoma* 2011;2011:1-6. Available from: <https://www.hindawi.com/journals/sarcoma/2011/959132>. Accessed on Feb 15, 2018.
- Taib F, Mohamad N, Mohamed Daud MA, Hassan A, Singh MS, Nasir A. Infantile fibrosarcoma of the penis in a 2-year-old boy. *Urology* 2012;80:931-3. [DOI: 10.1016/j.urology.2012.05.021].
- Stivala A, Lombardo GA, Pompili G, Tarico MS, Frassetto F, Perrotta RE. Dermatofibrosarcoma protuberans: Our experience of 59 cases. *Oncol Lett* 2012;4:1047-55. [DOI:10.3892/ol.2012.887].
- Palmerini E, Gambarotti M, Staals EL, Zanella L, Sieberova G, Longhi A, et al. Fibrosarcomatous changes and expression of CD34+ and apolipoprotein-D in dermatofibrosarcoma-protuberans. *Clin Sarcoma Res* 2012;2:4. [DOI:10.1186/2045-3329-2-4].
- Dragoumis DM, Katsogi LA, Amfilanitis IK, Tsiptsoglou AP. Late local recurrence of dermatofibrosarcoma protuberans in the skin of female breast. *World J Surg Oncol* 2010;8:48. [DOI:10.1186/1477-7819-8-48].
- Franco JP, Barbosa CC, Fonseca BF, Lima RB, D'Acri AM, Martins CJ. Case for diagnosis. Dermatofibrosarcoma protuberans. *An Bras Dermatol* 2014;89:357-8.
- Chang CK, Jacobs IA, Salti GI. Outcomes of surgery for dermatofibrosarcoma protuberans. *Eur J Surg Oncol* 2004;30:341-5. [DOI: 10.1016/j.ejso.2003.12.005].
- DuBay D, Cimmino V, Lowe L, Johnson TM, Sondak VK. Low recurrence rate after surgery for dermatofibrosarcoma protuberans: a multidisciplinary approach from a single institution. *Cancer* 2004;100:1008-16.
- Chan IL, Carneiro S, Menezes M, Silva RS, Magalhães T, Cuzzi T et al. Dermatofibrosarcoma Protuberans: A Case Report. *Case Rep Dermatol* 2014;6:134139. [DOI:10.1159/000362900]. Available from: <https://www.karger.com/Article/Pdf/362900>. Accessed on February 15 2018.
- Kasper B, Lossignol D, Gil T, Flamen P, De Saint Aubain N, Awada A. Imatinibmesylate in a patient with metastatic disease originating from a dermatofibrosarcoma protuberans of the scalp. *Anti-cancer Drug* 2006;17:1223-5. [DOI: 10.1097/01.cad.0000231486.94191.65].
- Ng A, Nishikawa H, Lander A, Grundy R. Chemosensitivity in pediatric dermatofibrosarcoma protuberans. *J Pediatr Hematol Oncol* 2005;27:100-2.