

Variation in Calibre of Arteries of Circle of Willis with Age: An MRA Based Study

Aisha Hassan Brohi¹, Kevin Joseph Jerome Borges², Nuzhat Hassan³, Muhammad Ali⁴,
Syed Nudrat Nawaid Shah⁵, Gulraiz Hikmat Yar⁶

Abstract

Objective: To establish reference range for the diameters of arteries forming the Circle of Willis (CoW) and to correlate it with age.

Methods: This cross-sectional study was conducted at the Radiology Department from January to July 2018. It comprises of patients referred for MR imaging of brain without any manifestation of cerebrovascular diseases. Patients who were claustrophobic or had a history of atherosclerosis, vasculitis, thrombus, aneurysm, arteriovenous malformation (AVM), intracranial tumour, diabetes and hypertension were excluded. 300 individuals comprising both males and females with mean age of 45 ± 11.6 (years) were recruited via non-probability sampling technique. Three-dimensional Time of Flight (TOF) Magnetic Resonance Angiography (MRA) was performed. Diameters of all component vessels forming the Circle of Willis were measured.

Results: The diameter of the anterior cerebral, anterior communicating, internal carotid, posterior communicating, posterior cerebral and basilar arteries were found to be 1.51 ± 0.28 mm, 1.05 ± 0.37 mm, 3.69 ± 0.23 mm, 1.10 ± 0.11 mm, 1.85 ± 0.23 mm, 3.00 ± 0.11 mm respectively. Spearman correlation demonstrated that the diameters of the arteries were significantly correlated with age in different ways. Significant moderate positive correlations of internal carotid and basilar artery diameters were seen with age. Significant weak negative correlations were seen in anterior and posterior cerebral arteries. Significant very weak negative correlations were seen in anterior and posterior communicating artery diameters and age.

Conclusion: The normal reference values for vessels diameter of CoW were determined in general population living in Karachi. Diameter of the arteries showed statistically significant correlation with age in different ways. Knowledge of calibre of the arteries is helpful in cerebrovascular surgeries and radiological neuro interventions.

Keywords: Circle of willis, magnetic resonance angiography, arteries.

IRB: Approved by the Ethical Review Committee of Ziauddin University, Ref Code: 0470118AHANA.

Dated: 26th January 2018.

Citation: Brohi AH, Borges KJJ, Hassan N, Ali M, Shah SNN, Yar GH. Variation in Calibre of Arteries of Circle of Willis with Age: An MRA Based Study [Online]. *Annals ASH KMDC* 2018;23:

(ASH & KMDC 23(4):184;2018)

Introduction

With the advent of minimal invasive surgeries and radiological neuro-interventions, the knowledge of morphology and morphometry of cerebral vasculature at the base of brain, commonly known as the Circle of Willis (CoW) is essential for radiolo-

^{1,2,3,5} Department of Anatomy,

^{4,6} Department of Radiology,
Ziauddin University

Correspondence: Dr. Aisha Hassan Brohi
Department of Anatomy, Ziauddin University

Email: aishahassanbrohi@gmail.com

Date of Submission: 26th October 2018

Date of Acceptance: 17th January 2019

gists and neurosurgeons while performing various diagnostic and interventional procedures. A surgeon's assessment of the feasibility of shunt installation requires a thorough prior knowledge of the normal size and calibre of these vessels¹. Previous studies have shown that cerebral vasculature shows considerable variations in its morphology as well as in the luminal diameters of the arteries. Vessels generally vary in calibre and are may be hypoplastic (diameter less than 0.7 mm) or aplastic²⁻⁴. In diagnosis and management of cerebrovascular accidents, TIA and haemorrhagic stroke awareness about these

variations plays a critical role and may help in surgical planning^{5,6}.

The brain is supplied by anterior and posterior circulations, formed by vessels of the 'circle of Willis' named after Dr. Thomas Willis who first described its anatomical and physiological significance⁷. The CoW lies in the interpeduncular fossa and is formed by right and left internal carotid arteries (ICA), each of which branches to give anterior cerebral arteries (ACA). The two right and left ACAs communicate via anterior communicating artery (AComA) thereby forming anterior circulation, supplying blood to anterior part of the brain⁸. The posterior circulation is formed by the basilar artery, which branches to form right and left posterior cerebral arteries (PCA), supplying blood to the posterior part of the brain. The anterior and posterior circulations are connected to each other via a thin thread-like posterior communicating artery (PComA) which is a branch of ICA⁹.

Anterior cerebral artery is divided into an "A1 segment" - from its origin at the internal carotid till the junction with the anterior communicating artery and an "A2 segment" - the course distal to the junction with the anterior communicating artery. Likewise, the posterior cerebral artery is divided into a "P1 segment" - from the bifurcation of the basilar artery to the junction with the posterior communicating artery and a "P2 segment" - from the junction with the posterior communicating artery to the portion in the perimesencephalic cistern¹⁰.

The calibre of the posterior communicating artery is smaller than that of the posterior cerebral artery. An inverse relation exists between the calibre of PCA and PComA which ensures better supply to hindbrain. Previous studies have shown variations in the calibre of two arteries. It is essential to have knowledge of such variations as any thrombotic material arising from the internal carotid artery can go to the P2 segment of PCA via the larger calibre of the PComA¹¹.

The circle of Willis provides an essential pathway to maintain collateral flow which becomes ex-

tremely significant in cases of vessel occlusion due to atherosclerosis and thrombosis. The PComA and AComA play a crucial role in establishment of collateral circulation. Imaging techniques like magnetic resonance angiography (MRA), cranial tomography angiography (CTA) and Transcranial coded duplex ultrasound (TCCD) has enabled the radiologists to accurately assess the hemodynamic and morphological information of individual vessels¹². Amongst these, MRA is a non-invasive technique which without using ionizing radiations is not only used to assess abnormalities in the cerebral arterial blood vessels, but is also capable of visualizing and calibrating smaller blood vessels with high quality images¹³. This is widely used to study brain vessels, as it does not require contrast injection. MRA confirms the anatomical variations of CoW, which may provide basis for future prognosis and treatment of cerebrovascular diseases¹⁴. 3D TOF MRA improves the contrast between flowing blood and stationary effect of blood flow allowing smaller blood vessels to be visualized easily. The imaging principle of MRA is to detect blood flow influenced by the diameters of blood vessels. TOF MRA can detect smaller blood vessels with diameter as small as 0.7mm¹⁵. The use of high tesla MRA machines yields high quality images with better details allowing for the study of smaller vessels¹⁶. Due to these qualities, MRA is considered as a superior modality amongst rest of the imaging techniques.

The present study was conducted to determine the diameter of the vessels of CoW using 3D TOF MRA and to correlate it with age.

Subjects and Methods

This was a cross-sectional study carried out at the Radiology from January to July 2018. Sample size was calculated by using WHO sample size calculator keeping confidence interval at 95% and bound of error at 6%. A total of 300 participants were recruited by using non-probability convenience sampling technique. It included 177 males and 123 females of ages between 20 to 60 years, without any known cerebrovascular disease. Primarily in-

cluded were those referred with complaints of headache, epilepsy or metastasis. Patients who were claustrophobic or had a history of atherosclerosis, vasculitis, thrombus, aneurysm, AVM, intracranial tumour, diabetes and hypertension were excluded.

The study was initiated after approval from the Ethics Review Committee. Informed written consent was obtained from every participant. 3D TOF MRA brain were taken using spoiled gradient recalled acquisition (SPGR) sequence on 1.5 high Tesla MR scanner (Avento, Siemens Germany). MRA examination was performed with standard head coil. MRA protocol consisted of non-contrast 3D TOF transaxial acquisition used for examination of all patients. All component vessels of the CoW were accessed on maximum intensity projection MIP, as well as TOF source images on workstation (Fig. 1). Diameters of the arteries were measured after proper magnification and were measured as follows: Internal carotid arteries (ICA) in the cavernous segment; A1 (anterior cerebral artery first segment); P1 (posterior cerebral artery first segment) in the first cm segment; basilar arteries just inferior to where it gives a branch to the superior cerebellar artery. Posterior communicating artery (PCoA) where it arises from ICA.

Data was analysed on SPSS version 20. Quantitative data is given in mean and standard deviation. As the collected data was unequally distributed, Spearman correlation was used to correlate age with arterial diameter. In all analysis, a p-value of <0.05 was considered to be significant.

Results

Out of 300 individuals, 59% (177) were males and 41% (123) were females with mean age 45.07 ± 11.06 ranging from 20 to 60 years. Mean diameter of paired arteries was taken. The mean diameter of different components of CoW was found to be as follows: ACA 1.51 ± 0.28 mm, ACoMA 1.05 ± 0.37 mm, ICA 3.69 ± 0.23 mm, PCoMA 1.10 ± 0.11 mm, PCA 1.85 ± 0.23 mm, BA 3.00 ± 0.11 mm (Table 1). By using Spearman correlation, a signifi-

cant weak negative correlation was seen between the mean diameter of anterior cerebral artery and age ($r = -0.415$, $p = 0.001$). A significant very weak negative correlation was observed between the mean diameter of ACoMA and age ($r = -0.156$, $p = 0.032$). A significant moderate positive correlation was seen between mean diameter of ICA and age ($r = 0.680$, $p = 0.001$). A significant very weak negative correlation was seen between mean diameter of PCoMA and age ($r = -0.258$, $p = 0.038$). A significant weak negative correlation was seen between mean diameter of PCA and age ($r = 0.528$, $p = 0.001$). A significant moderate positive correlation was seen between mean diameter of BA and age ($r = 0.679$, $p = 0.001$). These have been shown in Figure 2.

Discussion

Many studies have been published on anatomical variations of component vessels of CoW regarding their formation, patency and calibre of the vessels in different populations. These variations in diameter of the vessels could be due to hemodynamic and ageing factors such as blood pressure and loss of elasticity of vessel wall¹⁷. Knowledge of such variations are important in specific populations as these are required for many radiological neuro-interventions and surgical procedures like AVM embolization, microsurgical clipping and in cases of tumour excision¹⁸. Present study was conducted to establish a reference range of the diameters of different vessels of CoW for our set of population.

In our study diameter of ACA was found to be 1.51 ± 0.28 mm. This is comparable to the results reported by Yeniçeri et al¹⁹ MRA based study from Turkey showing ACA diameter as 1.58 to 1.6 mm. However, cadaveric studies from Turkey²⁰ and India⁵ have reported a diameter of 1.8 ± 0.48 mm and 2.8 ± 0.09 mm respectively which differs from our results. MRA based studies from Australia²¹ and Brazil²² also showed a higher value of ACA diameter than ours.

ACoMA is an important communicating channel between right and left ACAs. In our study, ACoMA diameter was found to be 1.05 ± 0.37 mm.

Table 1. Mean arterial diameter of different arteries of CoW and their correlation with age

Variables	N	Mean	Std. Deviation	Correlation co- efficient (with age)	p-value
Age (Years)	300	45.07	11.63	1.00	
ACA Diameter (mm)	300	1.51	0.28	-0.41	0.00*
ACoMA Diameter (mm)	300	1.05	0.37	-0.15	0.01*
ICA Diameter (mm)	300	3.60	0.23	0.68	0.00*
PCoMA Diameter (mm)	300	1.10	0.11	-0.25	0.00*
PCA Diameter (mm)	300	1.85	0.23	-0.52	0.00*
Basilar Diameter (mm)	300	3.00	0.11	0.67	0.00*

N; number of participants, ACA; Anterior cerebral arteries, ACoMA; Anterior communicating artery, ICA; Internal carotid artery, PCoMA; Posterior communicating artery, PCA; Posterior cerebral artery, *p-value; <0.05 is considered significant

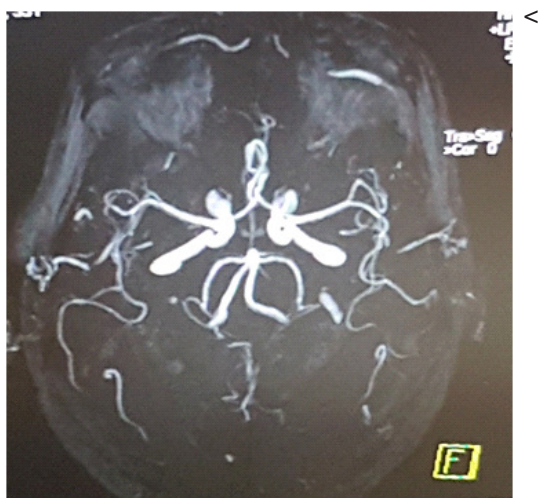

Fig 1. MRA showing the vessels of the circle of willis

When we compared our results with data from previous studies a larger diameter was observed in other populations. In cadaveric studies by Gunnal et al in Indian population and by Karatas et al in Turkish population, it was found to be 1.7 ± 0.08 mm and 1.43 ± 0.60 mm respectively. One of the reasons for the differences in diameters observed above could be due to the fact that MRA is more accurate as compared to cadaveric study.

ICA diameter in our population was found to be 3.69 ± 0.23 mm which is comparable to that of a cadaveric study from Turkey (3.59 ± 0.65 mm). We could not find any MRA based study showing comparable ICA diameter. However, larger diameters of ICA have been reported by different MRA based studies El-Barhoun et al from Australia (4.5 mm), and Yeniceri et al from Turkey (4.24 mm). Larger diameter of ICA has also been reported by cadav-

eric study by Gunnal et al from India (4.9 ± 0.07 mm). This suggests that diameter of arteries varies from population to population.

In initial stages of development, all segments of CoW have equal diameters but with growth and increasing functional demands of the occipital lobe the, PCA or PCoMA may increase or decrease its size according to hemodynamic conditions²³.

PCoMA provides important anastomosing channel between anterior and posterior circulations. Its diameter in our study was found to be 1.10 ± 0.11 mm which is in agreement with the results of Yeniceri et al who have reported the diameter of PCoMA as 1.12 mm Whereas Gunnal et al and Sandhya et al²⁴ have reported significantly higher values of PCoMA diameter.

PCA diameter in our study was found to be 1.85 ± 0.23 mm which is comparable to the results of two Turkish studies by Yeniceri et al (MRA study) and Karatas et al (cadaveric study). However El-barhoun et al from Australia (MRA study), Stefani et al from Brazil (MRA study) and Gunnal et al from India (cadaveric study) have reported a larger PCA diameter than ours.

We report BA diameter as 3.0 ± 0.11 mm which is more or less similar to that reported by El-barhoun et al (3.1 mm) and Stefani et al (2.9 ± 0.09 mm). Our observations differ from those of Karatas et al, Gunnal et al and Yeniceri et al who found the diameter of BA as 3.6 ± 0.65 mm, 4.9 ± 0.06 mm, and 2.8 mm respectively.

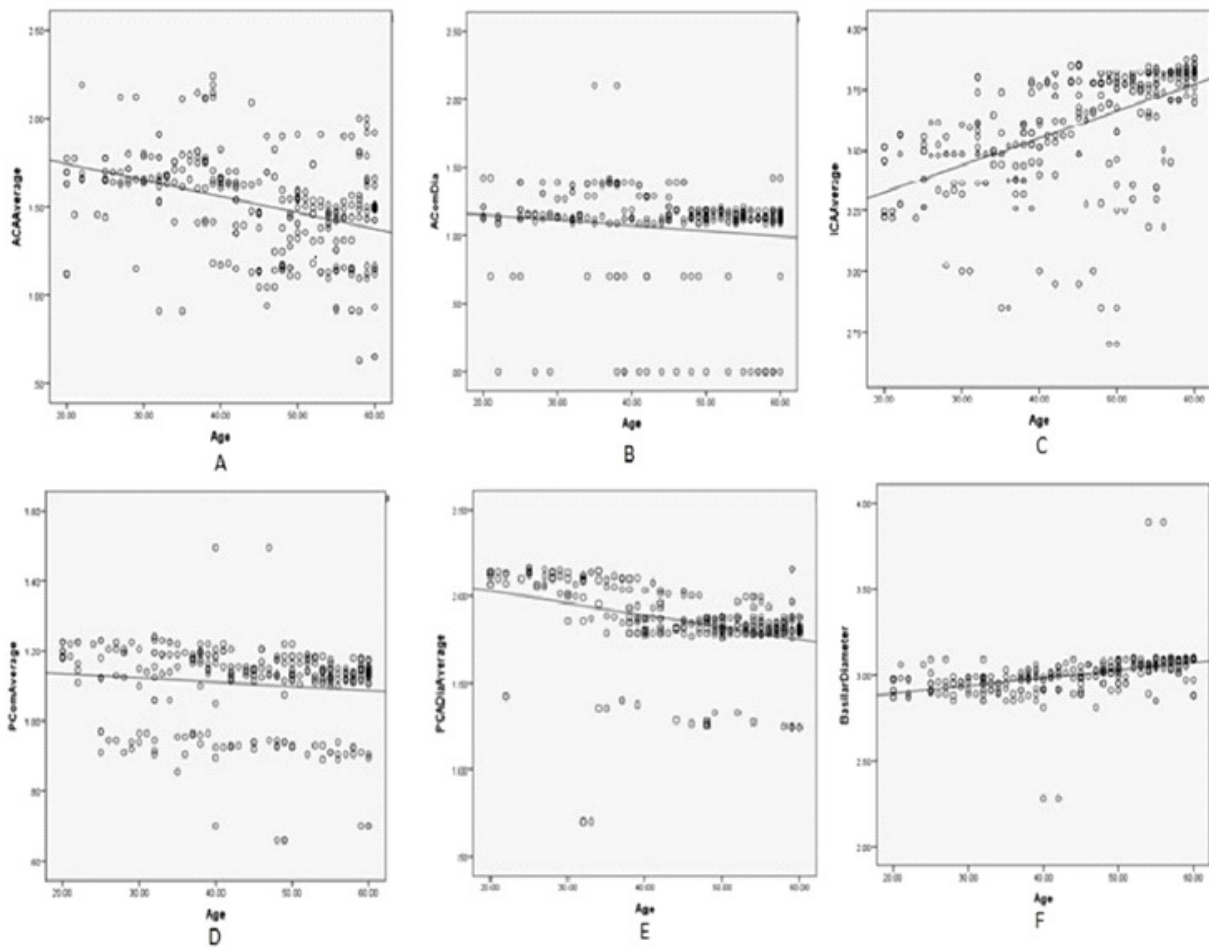


Fig 2. Scatter plot representing correlation of diameter of vessels of circle of willis with age.

Scatter plots showing correlation between mean diameters of arteries of CoW with age. A) Showing a significant weak negative correlation between the mean diameter of Anterior cerebral artery and age ($r = -0.415, p = 0.001$) B) Showing significant very weak negative correlation between the mean diameter of AComA and age ($r = -0.156, p = 0.032$), C) Showing significant moderate positive correlation between mean diameter of ICA and age ($r = 0.680, p = 0.001$), D) Showing significant very weak negative correlation between mean diameter of PComA and age ($r = -0.258, p = 0.038$), E) Showing significant weak negative correlation between mean diameter of PCA and age ($r = -0.528, p = 0.001$), F) Showing significant moderate positive correlation between mean diameter of BA and age ($r = 0.679, p = 0.001$)

Wide range of variations in different populations could be due to genetic, regional, embryological or combination of these factors and needs further research. One of the reasons for the differences in luminal diameters observed above could be because of the difference in cadaveric and imaging studies. In the presence of adequate blood pressure and blood flow, the arterial wall distends in imaging techniques whereas in autopsy based studies normal anatomy is distorted as a result of post-mortem changes. In cadaveric studies diameters are measured externally with vernier caliper

whereas in imaging studies luminal diameters are measured which is more accurate²⁵.

From these studies, it has been demonstrated that the calibres of different arteries forming the CoW differs in different populations. These variations could also be due to the methods and techniques such as anatomic dissections versus MR angiography. Moreover, this could also be due to selection of study population (studies performed in normal brains versus those of diseased ones). Finally, this could also be due to variations in the ages of the selected candidates.

It was also observed that the average diameter of the centripetal arteries (the right and left ICA and BA) were larger and tends to increase with age whereas the centrifugal arteries (ACA, PComA and PCA) were smaller. This could be due to compensatory enlargement in aged people because of reduced cardiac output and decreased elasticity with age. Knowledge of diameter of these arteries is required for the feasibility of shunt operations.

Conclusion

It is concluded that the mean diameter of different vessels of CoW varies significantly with age. A significant moderate positive correlation was seen between mean diameters of the centripetal arteries (ICA and BA) with age. A significant weak negative correlation was observed between mean diameters of the centrifugal vessels of CoW with age. Knowledge of such variations is critical for neurosurgeons, as well as for neuro-interventional radiologists.

Conflict of interest

The authors declare no conflict of interest, and all authors have studied and approved the final manuscript.

References

1. Van Ooij P, Zwanenburg J, Visser F, Majoie C, Vanbavel E, Hendrikse J, et al. Quantification and visualization of flow in the Circle of Willis: Time-resolved three dimensional phase contrast MRI at 7 T compared with 3 T. *Magn Reson Med* 2013;69:868-76. [DOI: 10.1002/mrm.24317].
2. Kumar APV, Prasad K. A Study of Variation of Circle of Willis, in the Adult Population of South India [Online]. *International Journal of Contemporary Medical Research* 2016;3:1448-1450. Available from: https://www.ijcmr.com/uploads/7/7/4/6/7/7/4/6/4/7/3/8/_a_study_of_variation_of_circle_of_willis_in_the_adult_population_of_south_india_.pdf. Accessed on: 30th December 2018.
3. Klimek-Piotrowska W, Rybicka M, Wojnarska A, Wójtowicz A, Koziej M, Hoda MK. A multitude of variations in the configuration of the circle of Willis: an autopsy study. *Anat Sci Int* 2016;91:325-33. [DOI: 10.1007/s12565-015-0301-2].
4. De Silva KRD, Silva R, Amaratunga D, Gunasekera W, Jayasekera RW. Types of the cerebral arterial circle (circle of Willis) in a Sri Lankan population [Online]. *BMC neurology*. 2011;11:5. Available from: <https://bmcneurol.biomedcentral.com/articles/10.1186/1471-2377-11-5>. Accessed on: 30th December 2018. [DOI: 10.1186/1471-2377-11-5].
5. Gunnal S, Farooqui M, Wabale R. Anatomical variations of the circulus arteriosus in cadaveric human brains [Online]. *Neurol Res Int* 2014;2014. Available from: <https://bmcneurol.biomedcentral.com/articles/10.1186/1471-2377-11-5>. Accessed on: 30th December 2018. [DOI: <http://dx.doi.org/10.1155/2014/687281>].
6. Zhou H, Sun J, Ji X, Lin J, Tang S, Zeng J, et al. Correlation between the integrity of the circle of Willis and the severity of initial noncardiac cerebral infarction and clinical prognosis [Online]. *Medicine (Baltimore)* 2016;95. Available from: <http://pt.wkhealth.com/pt/re/lww/gateway/landingpage.htm?jsessionid=cydbKsF7lcjQhJ3LvJQnNmBf9syxLk72wB6tHpp5R5G22nZsm2X4!-1591332709!181195629!8091!-1?sid=>. Accessed on: 30th December 2018. [DOI: 10.1097/MD.0000000000002892]
7. Iqbal S. A comprehensive study of the anatomical variations of the circle of willis in adult human brains. *Journal of clinical and diagnostic research* [Online]. *JClin Diagn Res* 2013;7:2423. Available from: https://www.jcdr.net/article_fulltext.asp?issn=0973-709x&year=2013&volume=7&issue=11&page=2423&issn=0973-709x&id=3563. Accessed on: 30th December 2018. [DOI: 10.7860/JCDR/2013/6580.3563]
8. Moore KL, Dalley AF, Agur AM. Head. In: Moore KL, Dalley AF, Agur AM editors. *Clinically oriented anatomy*. 5th ed. Philadelphia: Lippincott Williams & Wilkins;2013.p.882.
9. Prasad VN, Chhetri PK, Paudel A. Normal Variants of the Circle of Willis in patients undergoing CT Angiography [Online]. *Journal of College of Medical Sciences-Nepal* 2017;13:190-2. Available from: <https://www.nepjol.info/index.php/JCMSN/article/download/16659/1375>. Accessed on: 30th December 2018. [DOI:<http://dx.doi.org/10.3126/jcmsn.v13i1.16659>]
10. Standring S. Neuroanatomy. In: Standring S, Anand N, Jawaheer G, Tubbs RS, Birch R, Smith AL et al. editors. *Gray's anatomy: the anatomical basis of clinical practice*. 41st ed. Elsevier Health Sciences;2015.p.280.
11. Al-Hussain SM, Shoter AM, Bataina ZM. Circle of Willis in adults [Online]. *Saudi Med J* 2001;22:895-8. Available from: https://www.unboundmedicine.com/medline/citation/11744950/Circle_of_Willis_in_adults_. Accessed on: 30th December 2018.

12. Klimek-Piotrowska W, Kope? M, Kochana M, Krzy?ewski R, Tomaszewski K, Brzegowy P, et al. Configurations of the circle of Willis: a computed tomography angiography based study on a Polish population. *Folia Morphol (Warsz)* 2013;72:293-9.
13. Kondori BJ, Azemati F, Dadseresht S. Magnetic Resonance Angiographic Study of Anatomic Variations of the Circle of Willis in a Population in Tehran. *ArchIranian Med* 2017;20:235. [DOI: 0172004/AIM.009.].
14. Saikia B, Handique A, Phukan P, Lynser D, Jamil M. Study of anomalies in the circle of Willis using magnetic resonance angiography in north eastern India [Online]. *J Anat Soc India* 2014;63:67-73. Available from: <https://www.sciencedirect.com/science/article/pii/S0003277814000483?via%3Dihub>. Accessed on: 30th December 2018. [DOI: <https://doi.org/10.1016/j.jasi.2014.05.007>].
15. Qiu C, Zhang Y, Xue C, Jiang S, Zhang W. MRA study on variation of the circle of Willis in healthy Chinese male adults. *Biomed Res Int* 2015;2015:976340. [DOI:10.1155/2015/976340.].
16. AlMuhanna K, Zhao L, Kowalewski G, Beach KW, Lal BK, Sikdar S. Investigation of cerebral hemodynamics and collateralization in asymptomatic carotid stenoses [Online]. *Engineering in Medicine and Biology Society (EMBC), 2012 Annual International Conference of the IEEE2012:5618-5621*. Available from: <https://ieeexplore.ieee.org/document/6347268/>. Accessed on: 30th December 2018. [DOI: 10.3889/oamjms.2017.160].
17. Poudel P, Bhattarai C. Anomalous formation of the circulus arteriosus and its clinico-anatomical significance. *Nepal Med Coll J* 2010;12:72-5.
18. Alawad AHM, Hussein MA, Hassan MA. Morphology and normal variations of the cerebral arterial circle "of Willis" in Khartoum Diagnostic Centre. *Khartoum Med J* 2012;2.<http://onlinejournals.uofk.edu/index.php/kmj/article/view/406/395>.
19. Yeni?eri IÖ, Çullu N, Deveer M, Yeni?eri E. Circle of Willis variations and artery diameter measurements in the Turkish population. *Folia Morphol* 2017;76:420-5. [DOI: 10.5603/FM.a2017.0004.].
20. Karatas A, Yilmaz H, Coban G, Koker M, Uz A. The anatomy of circulus arteriosus cerebri (circle of Willis): a study in Turkish population. *Turk Neurosurg* 2016;26:54-61. [DOI: 10.5137/1019-5149].
21. El?Barhoun E, Gledhill S, Pitman A. Circle of Willis artery diameters on MR angiography: an Australian reference database. *Journal of medical imaging and radiation oncology* 2009;53:248-60. [DOI: 10.1111/j.1754-9485.2009.02056.x.].
22. Stefani MA, Schneider FL, Marrone ACH, Severino AG. Influence of the gender on cerebral vascular diameters observed during the magnetic resonance angiographic examination of willis circle [Online]. *Braz Arch BiolTechnol*2013;56:45-52. Available from: <https://www.id-press.eu/mjms/article/view/oamjms.2017.160>. Accessed on: 30th December 2018. [DOI: 10.3889/oamjms.2017.160].
23. Takakuwa T, Koike T, Muranaka T, Uwabe C, Yamada S. Formation of the circle of Willis during human embryonic development. *Congenit Anom (Kyoto)* 2016;56:233-6. [DOI: 10.1111/cga.12165.].
24. Gunnal SA, Farooqui MS, Wabale RN. Anatomical variability of the posterior communicating artery [Online]. *Asian J Neurosurg* 2018;13:363. Available from: <http://www.asianjns.org/article.asp?issn=1793-5482;year=2018;volume=13;issue=2;page=363;epage=369;aulast=Gunnal>. Accessed on: 30th December 2018. [DOI: 10.4103/ajns.AJNS_152_16].
25. Shatri J, Bexheti D, Bexheti S, Kabashi S, Krasniqi S, Ahmetgjekaj I, et al. Influence of gender and age on average dimensions of arteries forming the circle of Willis study by magnetic resonance angiography on Kosovo's population [Online]. *Open access Maced J Med Sci* 2017;5:714. Available from: <https://www.id-press.eu/mjms/article/view/oamjms.2017.160>. Accessed on: 30th December 2018. [DOI: 10.3889/oamjms.2017.160].