

Trigeminal Neuralgia (TN): A Case Report on Short-Term Follow up

Shazia Sarwat Iqbal, Zubair Ahmad Abbasi

Abstract

Trigeminal neuralgia (TN) is one of the most common neuropathic syndromes. It is more common in females than males. This condition is described as a sudden severe pain, can be unilateral or it can be in the form of episodes. Patient conceive it as very severe pain which affects the quality of life and health status of the individual. The pain can be described as a sudden severe pain which is normally triggered by a slight stimulus like touch, eating, drinking, washing, and shaving or by any thermal changes.

We report a case of a sixty five years old female patient who presented with right sided pain in upper and lower quadrant of the jaw which was not relived by medication. Investigations and regular follow up has revealed classical trigeminal neuralgia pattern.

Keywords: Trigeminal neuralgia, facial pain, a typical pain. (ASH & KMDC18(2):92;2013).

Introduction

Trigeminal neuralgia (TN) is a unilateral severe, penetrating pain and usually occurs in the distribution of one or more branches of the fifth cranial nerve. According to the International Association of pain the duration of the pain attacks last from a few seconds to two minutes and can recur without any visible cause¹. TN commonly affects individuals over 60 years of age and above. It is more frequent in women than men with a ratio of 1.5-2:1, respectively².

The facial pain is idiopathic in origin, and character of the pain is typical i.e. persistent, dull and poorly localized facial pain without sensory or other neurological deficit come in this domain. Therefore, it is essential to do investigation such as X-ray of face and jaws, cranial computer tomography (CT) or Magnetic resonance imaging (MRI) to exclude any relevant abnormality³.

The estimation of the prevalence of TN is very difficult. The incidence of TN is about 4-5 per 100,000 people per annum with an age range of 60-70 years⁴⁻⁷.

Diagnosis of TN is based on history of characteristic pain attacks which are consistent. The results of the investigations done are also unremarkable. As the cause of TN is unknown but vascular compression of trigeminal nerve roots are often considered to be the cause⁸. Most patients respond well to carbamazepine. Second line therapy comprises of baclofen, gabapentin, lamotrigine and phenytoin. However, radio surgery also plays an important role in the treatment of TN.

This report aims to estimate the factors which lead to TN, and to analyze the correlation between severity of risk factor and socio economical status, environment around the patient, type of diagnostic tools used and treatment rendered for TN. This report also encompasses the increasing incidence and prevalence of this disease however limitation of this case report cannot be ignored as it is a short follow up case report of the patient diagnosed of trigeminal neuralgia. Reports like these will in future

Department of Oral Surgery,
Karachi Medical & Dental College Hospital, Karachi.

Correspondence: Dr. Shazia Sarwat
Karachi Medical & Dental College, Karachi.
E-mail: iqbalnaseem54@gmail.com

help us from misdiagnosing the TN cases without confusing it with any other cause of persistent severe facial pain. Outlining the investigation and treatment plan will help in a definitive diagnosis of cases of TN.

Case Report

A 65 years old, well-oriented female patient from a low socio economical status reported to the department of Oral Maxillofacial Surgery of Abbasi Shaheed Hospital with a history of facial pain on the right upper and lower quadrant of face. Since 4 years she was hypertensive and cardiac patient. On examination face appeared symmetrical with no bony deformity. On examination oral hygiene was poor. (Fig) The patient had previously sought treatment from medical doctors who were unable to provide pain relief. Four years back she had mandibular swelling on the right side of the face involving the whole neck with pus discharge for which she was treated by incision and drainage. Since then patient had been suffering from recurrent facial pain, this pain was triggered by actions such as washing the face, touching the cheeks or during meal time. She had no prior history of headache and there was no family history of trigeminal neuralgia. MRI of brain reported dolicoectasia of the basilar artery causing compression effect over entry zone of right trigeminal nerve involving maxillary nerve (V2) and mandibular nerve (V3). The patient was then referred to Department of neurosurgery where she was prescribed Tab. Tegral 200mg three times a day (tds); Cap Regab 75mg twice a day, Tab Stemetil 5mg tds and advised follow up. On follow up visit patient still had pain and was given injection Depo-Medrol (methyl prednisolone acetate) 40mg/ml following which the patient was pain free for 6 months. Patient was advised to continue the same oral medicines prescribed earlier.

Discussion

Persistent severe facial pain is common, and patients with these symptoms are too lazy to visit their doctor for advice. Therefore it is very important to take a proper history and do physical examina-

tion which is the most effective tool in diagnosing cases of TN. However, confusion can arise in determining pain due to migraine, trigeminal neuralgia, atypical facial pain and cluster headaches with clinical certainty⁹. The symptoms of these conditions may overlap, as in our patient and the various causes of the facial pain may also share some common treatments¹⁰. The cause of trigeminal neuralgia is not fully clear it was thought to be due to irritation or compression of the trigeminal nerve root by surrounding arteries¹¹.

In our patient the dolicoectasia of the basilar artery caused compression over entire zone of right trigeminal nerve involving V2 and V3. There is a theory which suggests peripheral nerve injury or disease of the trigeminal nerve, increased afferent firing probably by ephaptic transmission between afferent unmyelinated axons and partially damaged myelinated axons. Trauma or prior surgical procedures to the face have been associated with TN type symptoms referred to as Atypical TN, Trigeminal 'Neuropathy' or Post Traumatic TN. This is seen following cranio-facial trauma, dental trauma, sinus trauma and post rhizotomy (used for treating TN). In our patient both compression and trauma after surgery resulted in severe pain.

Permanent damage to the trigeminal nerve and secondary hyperactivity of the trigeminal nerve nucleus, may result in Atypical TN, Trigeminal 'Neuropathy' or Post Traumatic TN¹². It is useful to rule out any other potential etiology such as tumor or demyelination disease. More advanced MRI can identify the presence of vascular compression at the root entry zone. However, decision for surgical exploration remains a purely clinical diagnosis irrespective of MRI presence of vascular compression¹³.

Medical therapy is the initial treatment of choice which includes anti-convulsant drugs. Carbamazepine i.e the only anti epileptic medication with proven efficacy in different type trials involved in the management of TN Therefore carbamazepine is a first line therapy¹⁴ for TN. It stabilizes inactivated voltage-gated sodium-channels

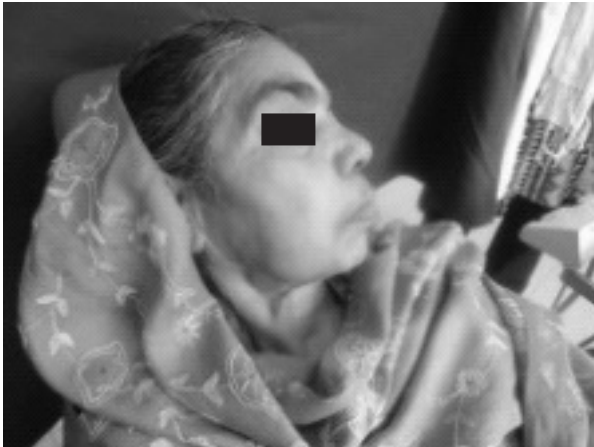


Fig A: Shows normal right side of the symmetrical face V2, V3 (maxillary and mandibular nerve) division

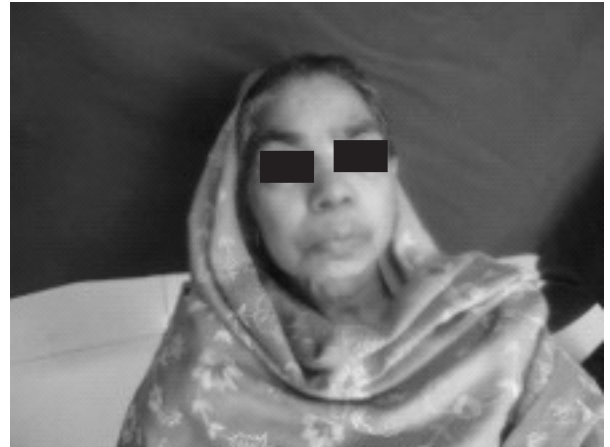

Fig B: Frontal view showing the symmetry of the face

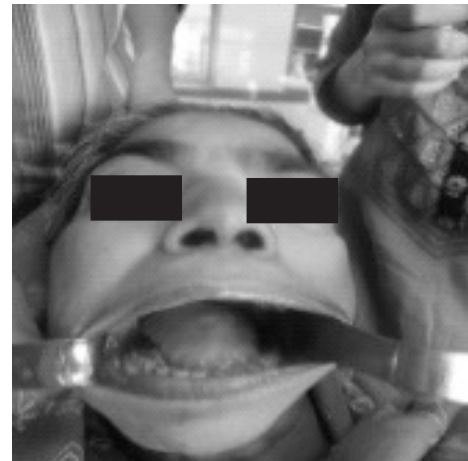
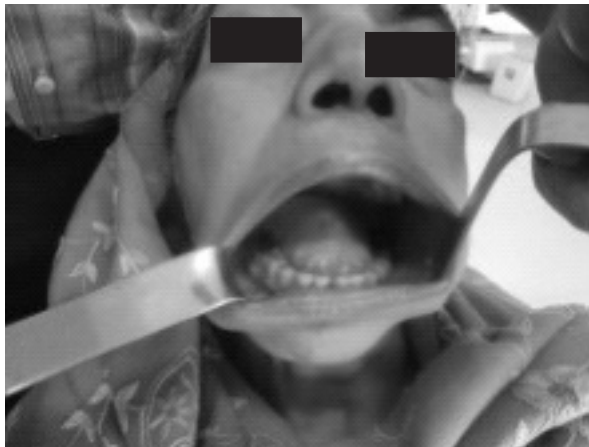
Fig C and D: Showing no dental problem i.e. no caries and periodontal problem.

down-regulatory cellular excitability¹⁵. This drug also helped our patient.

Alternative medication includes Oxcarbazepine, Baclofen, Gabapentin, Lamotrigine and Pimozide in combination.

Around 75% of patients show partial improvement after taking this drug but on prolonged use its efficiency decreases. Different types of medication are also used in the absence of definitive clinical evidence¹⁶. Failure of medical therapy leads to more invasive treatment options.

If pharmacological treatment does not provide satisfactory pain relief from TN then surgical treatment is often suggested. Gamma knife surgery is a non invasive technique that focuses a beam of radiation at trigeminal root in the posterior fossa¹⁷.

Diagnosis and treatment of Trigeminal neuralgia remains to be challenge for physicians to improve functions and quality of life for afflicted patient¹⁸.

Conclusion

Trigeminal neuralgia may have an unusual presentation and it is difficult to relieve the pain asso-

ciated with it. Investigation and treatment guidelines will help in early diagnosis and treatment of TN.

References

1. Lefaucheur JP, Hatem S, Nineb A, Menard-Lefaucheur I, Wendling S, Keravel Y, et al. Somatotopic organization of the analgesic effects of motor cortex rTMS in neuropathic pain. *Neurology* 2006;67:1998-2004.
2. Krafft RM. Trigeminal neuralgia. *Am Fam Physician* 2008;77:1291-6.
3. Headache Classification Subcommittee of the International Headache Society. The International Classification of Headache Disorders: 2nd edition. *Cephalalgia* 2004;24:9-160.
4. Kalyanaraman S, Ramamurthi B. *Neurol India* 1970;18:100-8.
5. MacDonald BK, Cockerell OC, Sander JW, Shorvon SD. *Brain* 2000;123:665-76.
6. Katusic S, Beard CM, Bergstralh E, Kurland LT. *Ann Neurol* 1990;27:89-95.
7. Hall GC, Carroll D, Parry D, McQuay HJ. *Pain* 2006;122:156-62.
8. Love S, Coakham HB. Trigeminal neuralgia: pathology and pathogenesis. *Brain* 2001;124:2347-60.
9. Feinmann C, Peatfield R. Orofacial neuralgia. Diagnosis and treatment guidelines. *Drugs* 1993;46:263-8.
10. Rosen TD. Antiepileptic drugs in the management of cluster headache and trigeminal neuralgia. *Headache* 2001;41:25-32.
11. Kanai A, Saito M, Hoka S. Subcutaneous sumatriptan for refractory trigeminal neuralgia. *Headache* 2006;46:577-82.
12. A M Kaufmann, M Patel. Trigeminal Neuralgia [Internet]. Centre for Cranial Nerve Disorders. Winnipeg: University of Manitoba. Health Sciences Centre. c2001. Available from: http://www.umanitoba.ca/cranial_nerves/trigeminal_neuralgia/index.htm.
13. Benjamin MZ, Yaron AM. Trigeminal Neuralgia: Case report and review. *JHN journal* [Internet]. 2012;7:3. Available from: <http://jdc.jefferson.edu/jhnj/vol7/iss2/3>.
14. Wiffen PJ, Derry S, Moore RA, McQuay HJ. Carbamazepine for acute and chronic pain in adults. *Cochrane Database Syst Rev* 2011;1:CD005451.
15. Blom S. Tic douloureux treated with new anticonvulsant; experiences with G 32883. *Arch Neurol* 1963;9:285-90.
16. Canavero S, Bonicalzi V. Drug therapy of trigeminal neuralgia. *Expert Rev Neurother* 2006;6:429-40.
17. Cruccu G, Gronseth G, Alksne J, Argoff C, Brainin M, Burchiel K, et al. AAN-EFNS guidelines on trigeminal neuralgia management. *Eur J Neurol* 2008;15:1013-28.
18. Michiels WB, McGlithlen GL, Platt BJ, Grigsby EJ. Trigeminal neuralgia relief with intrathecal ziconotide. *Clin J Pain* 2011;27:352-4.